

Conscious Neurosensory Mapping of the Internal Structures of the Human Knee Without Intraarticular Anesthesia

Scott F. Dye,*†‡ MD, Geoffrey L. Vaupel,† MD, and Christopher C. Dye§

From the *Department of Orthopaedic Surgery, University of California, and †Division of Orthopaedic Surgery, California Pacific Medical Center, Davies Campus, San Francisco, California, and §Mira Costa College, Oceanside, California

ABSTRACT

The conscious neurosensory characteristics of the internal components of the human knee were documented by instrumented arthroscopic palpation without intraarticular anesthesia. With only local anesthesia injected at the portal sites, the first author (SFD) had both knees inspected arthroscopically. Subjectively, he graded the sensation from no sensation (0) to severe pain (4), with a modifier of either accurate spatial localization (A) or poor spatial localization (B). The nature of the intraarticular sensation was variable, ranging from 0 on the patellar articular cartilage to 4A on the anterior synovium, fat pad, and joint capsule. The sensation arising from the cruciate ligaments ranged from 1 to 2B in the midportion, and from 3 to 4B at the insertion sites. The sensation from the meniscal cartilages ranged from 1B on the inner rim to 3B near the capsular margin. Innervation of most intraarticular components of the knee is probably crucial for tissue homeostasis. Failure of current intraarticular soft tissue reconstructions of the knee may be due, in part, to the lack of neurosensory restoration. Research studies of the knee designed to delineate factors that restore neurosensory characteristics of the musculoskeletal system may lead to techniques that result in true restoration of joint homeostasis and function.

The human knee is one of the most complex systems in the body. The asymmetrical components of the knee act in concert as a type of biologic transmission that accepts, transfers, and dissipates loads among the femur, tibia,

patella, and fibula.⁹ The ligaments act as adaptive linkages, with the menisci representing mobile bearings. Current data indirectly indicate that various intraarticular components of the knee are sensate, that is, they generate neurosensory signals that reach the spinal, cerebellar, and higher central nervous system levels. These signals ultimately result in conscious perception. The main research studies supporting this belief have been based on histologic evidence of neural structures within intraarticular components,^{4,7,14-17,19,20,23,26,29,34,35} the documentation of sensory evoked potentials,²⁶ or on proprioceptive characteristics of the human knee.^{2,3,6,24,27,30,31} Proprioceptive studies have been primarily designed to elicit conscious detection of small movements of the knee. Such data summarize neurosensory output from the entire joint and limb, including the extraarticular structures; thus, they do not isolate possible intraarticular sensory signals. Documentation of sensory evoked potentials with electrical stimulation of intraarticular structures of anesthetized patients at surgery does not address the question of whether and to what extent a person would consciously experience palpation of those structures.

We (SFD and GLV) concluded that a simple method to directly document possible conscious neurosensory perception of the intraarticular components of the human knee would be to arthroscopically palpate the components without intraarticular anesthesia and record the subjective experience. We are aware of no prior studies that have attempted such neurosensory documentation. Our purpose, therefore, was to document conscious neurosensory mapping of the intraarticular components of the human knee by means of arthroscopic instrumented palpation without intraarticular anesthesia.

MATERIALS AND METHODS

Both knees of the first author (SFD) were inspected arthroscopically by the second author (GLV). The right knee

‡ Address correspondence and reprint requests to Scott F. Dye, MD, California Pacific Medical Center, Davies Campus, 45 Castro Street, Suite 117, San Francisco, CA 94114.

No author or related institution has received any financial benefit from research in this study.

was inspected first, followed 1 week later by inspection of the left knee. This study was conducted at California Pacific Medical Center, Davies Campus, in San Francisco, California, with the approval of the human research director. The subject was a 46-year-old man at the time of the investigation. Both knees were asymptomatic and had documented normal preoperative radiographs and technetium 99m-methylene diphosphonate scintiscans. The only history of prior trauma to either knee was documented penetration of the medial facet of the right patella with a 15-gauge Jam-Shidi needle, which occurred 10 years earlier during a research project measuring intraosseous pressure. Residual discomfort from the medial facet penetration resolved fully 7 months after that investigation.

To minimize tissue trauma, only two portals, the anterolateral and anteromedial parapatellar, were used. Sterile lactated Ringer's solution, warmed to 90°F, at a pressure of 80 mm Hg was injected through the scope barrel (Stryker high flow arthroscopic barrel, Stryker Corp. of America, Santa Clara, California). On the right knee, 10 ml of 1% lidocaine with 1:100,000 epinephrine was used to provide local anesthesia at the portal sites. We attempted to avoid anesthetizing the anterior synovium or fat pad. Because the subject experienced lancinating pain on penetration of the anterior soft tissues with this method on the right knee, we used an alternative method of achieving local anesthesia at the portal sites for the left knee. One percent lidocaine with 1:100,000 epinephrine was used with 1 ml of Omnipaque 350 (Nycomed Pharmaceutical, New York, New York) added per 4 ml of lidocaine. The lidocaine-Omnipaque mixture (20 ml) was injected into the anterior synovium and fat pad of the left knee. Multiple CT images were obtained to document that the local anesthesia mixture remained within the anterior synovium and fat pad, and that it did not reach the intra-articular environment.

One of the coauthors (CCD) designed, built, and calibrated a spring-loaded device to produce a 0- to 500-g force. This device was attached to a standard straight arthroscopic probe with a distal tip footprint of 1 × 3 mm.

A knee holder (Instrument Makar, Okemos, Michigan) without a tourniquet was used for both knee examinations. The knees were sterilely prepared with betadine scrub followed by betadine solution and draped in standard sterile limb sheets. The subject was monitored throughout both procedures by an anesthesiologist (see "Acknowledgments," WTH for the right knee and JDW for the left knee), with intermittent determinations of blood pressure and continuous pulse oximeter evaluation. The subject received no sedative. A Stryker 810 Three Chip camera was used in connection with a Stryker Digital Photographic unit (Stryker Corp.) to provide the desired static images. Dynamic images were recorded on super VHS videotape.

The subject made an attempt to describe, as accurately as possible, where in the knee the sensation of palpation was occurring. The subjective sensation of palpated intra-articular structures was recorded verbally by the subject on a scale of 0 to 4: 0, no sensation; 1, nonpainful awareness; 2, slight discomfort; 3, moderate discomfort; and 4,

severe pain. A modifier of either A, for accurate spatial localization, or B, for poorly localized sensation, was also recorded. Finally, the sensation was mapped on two-dimensional schematics of the knee.

RESULTS

The conscious neurosensory perception of palpated intra-articular structures of the knee was the same in both knees. The degree of conscious neurosensory perception of the internal structures was variable, ranging from total absence of sensory perception to severe pain (Fig. 1). Penetration of the unanesthetized anterior synovium and fat pad region during the initial examination of the right knee produced severe pain that elicited involuntary verbal exclamations from the subject and nearly resulted in cessation of the study. Further documentation of this sensory finding in the left knee was thought to be unnecessary. Use of the local anesthetic technique described in the "Materials and Methods" section for the left knee resulted in a more tolerable portal entry experience for the subject. At no time was tissue removed from either knee.

Palpation of the patellar articular cartilage in the central ridge and medial and lateral facets resulted in no sensation, or a 0 score, even at 500 g of force. Palpation of the odd facets elicited a score of 1B. Asymptomatic grade II or III chondromalacia of the central ridge was identified on both patellas. Palpation of the suprapatellar pouch, capsule, and the medial and lateral retinacula produced a score of 3A to 4A (moderate to severe localized pain) at relatively low levels of force (<100 g). Palpation of the ACLs and exposed femoral insertion of the PCLs resulted in scores of 1B to 2B in the midregions. The scores increased to 3B and 4B at the tibial insertion and femoral origin sites at 500 g of force. The meniscofemoral ligament of Humphry was not identified. All four menisci revealed similar findings of 1B on the inner rim and up to 2B and 3B at the capsular margins and anterior and posterior horns at 300 to 500 g of force. Palpation of the articular cartilage surfaces of the femoral condyles, trochlea, and tibial plateaus at 500 g of force universally produced a sensation of 1B to 2B.

Additional qualitative subjective observations were noted during the two procedures. No discomfort was felt with the intraarticular fluid pressure of 80 mm Hg, or with the substantial varus and valgus directed vectors required to provide visualization of the medial and lateral compartments. An ill-defined, nonpainful, but intense sense of apprehension was experienced when the arthroscope was positioned between the patella and the central femoral trochlea. Only a position of forced full extension was tolerable with the arthroscope between the patella and trochlea. Even the slightest movement toward flexion resulted in the onset of increased discomfort and periarticular muscle spasms. A symptomatic effusion developed 2 days after the procedure on the left knee, but it resolved fully after aspiration of approximately 75 ml of a clear pink fluid. The subject has subsequently remained asymptomatic in both knees.

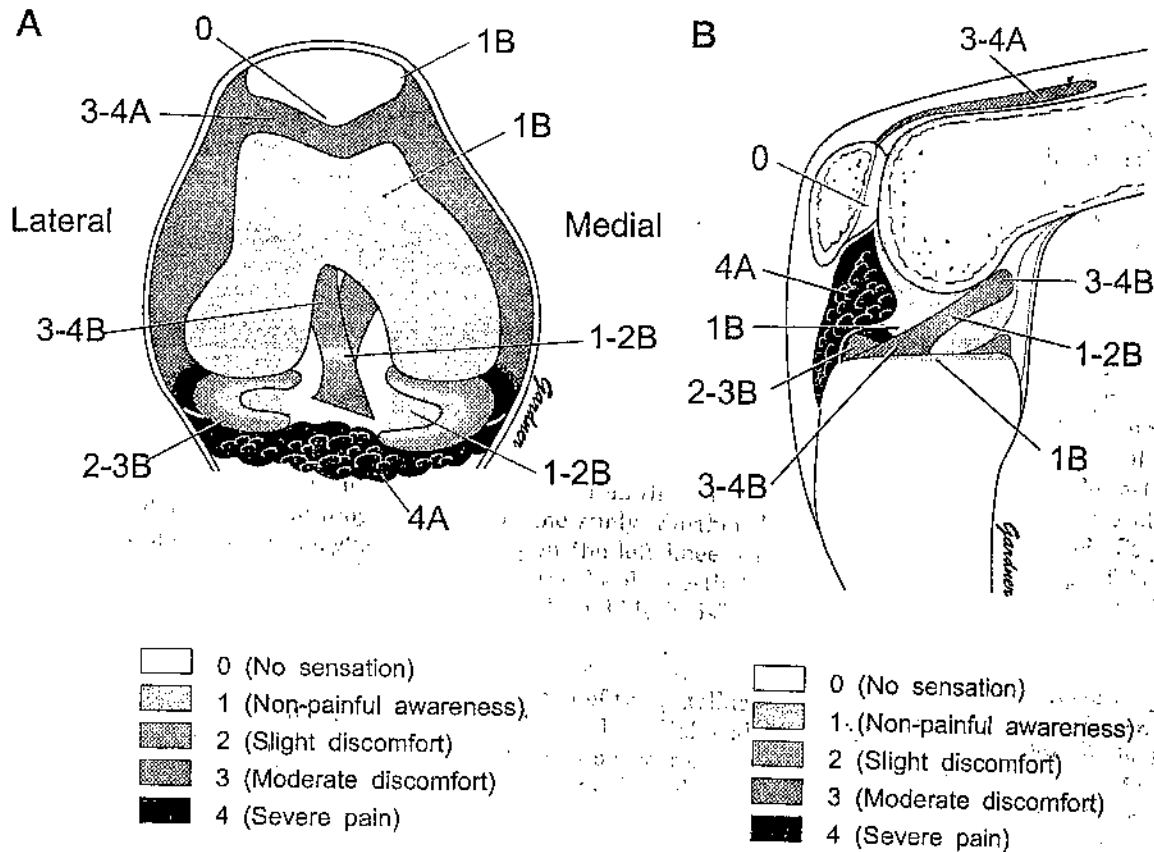


Figure 1. Coronal (A) and sagittal (B) schematic representations of the conscious neurosensory findings of the intraarticular structures of the knee. The right knee is illustrated. A, accurate spatial localization; B, poorly localized sensation.

DISCUSSION

This study confirms that most intraarticular structures of the human knee have sensory mechanisms that can result in conscious perception. Although the data were obtained from one subject, the conscious neurosensory perceptions were the same in both knees. Thus, the left knee experience validated the findings of the right knee. The data from prior studies have relied on indirect evidence of possible conscious perception of intraarticular structures, namely histology, sensory evoked potentials, and proprioceptive characteristics of the joint as a whole. This study, by probing the human knee without intraarticular anesthesia, provides direct evidence of the conscious perception of neurosensory output of internal structures. The anterior synovial tissues, fat pad, and capsule were exquisitely sensitive to the mechanical loading stimulus of the probe, whereas the sensation experienced with similar probing of the cruciate ligaments and menisci did not result in accurate spatial localization. This observation may provide an explanation for the often poor localization of structural damage that many patients experience with a cruciate ligament or meniscal injury. The painful synovitis and capsular inflammation frequently associated with a meniscal injury may be a more important factor in the subjective localization of the site of possible cartilage damage than sensation arising solely from the damaged meniscus.

We believe the quantitative data regarding loads produced at the palpated tissue should be viewed as estimates, in that an unknown degree of tissue resistance may have occurred at the probe-portal interface, particularly with positions close to full extension.

The reported conscious perceptions in this study, unlike purely objective data, are inherently and fundamentally subjective phenomena and, as such, raise a basic philosophical issue of epistemology (the theory of the nature of knowledge). The dilemma is discussed by the Austrian philosopher Wittgenstein,³² who recognized the point of view that one cannot be sure that the sensations one experiences (such as color, touch, pain) are the same as would be perceived by another individual under similar circumstances. Despite the philosophical limitations of reported conscious perceptions noted above, we, the authors, believe the findings of this study are probably true for most human knees, partly because of the extreme consistency and conservative nature of anatomic structure and function of the tetrapod knee over eons.¹⁰

We believe that the neurosensory capacity of the intraarticular structures of the human knee developed over millions of years through evolutionary mechanisms. These sensations provide not only joint telemetry of musculoskeletal subsystems for normal activities but also function as a negative feedback loop, alerting various components of the nervous system of deleterious mechanical (for ex-

ample, displaced meniscus) or chemical (for example, high cytokine levels) stimuli.²¹ Degradation of sensory output from the knee and other joints can eventually lead to structural failure of intraarticular components, as is seen in neuropathic joints associated with various diseases,^{5, 13, 22, 25, 33} or in those born with congenital insensitivity to pain.^{8, 18}

The information from this study can provide a basis for interpreting data from current and future research of the knee. We theorize that neurosensory innervation is important, and probably crucial, for normal joint function and maintenance of tissue homeostasis of most intraarticular structures of the knee. Lack of neurosensory restoration of certain intraarticular structures that have been surgically reconstructed or transplanted may lead to a common mode of eventual structural failure. A nonsensate reconstructed ACL or transplanted meniscus, for example, might be readily loaded to the point of structural damage without the presence of sensory output alerting the nervous system of dangerous mechanical loads. Such surgically created nonsensate structures could thus represent a neuropathic ligament or meniscus, which in many cases may eventually be destined to fail structurally with acute or repetitive supraphysiologic loads. Recent work by Barrack and coworkers¹ has demonstrated some limited and inconsistent return of neurosensory characteristics in ACL reconstruction in canines. No such findings have yet been shown in humans.

Joint proprioceptive mechanisms have been described as exquisitely sensitive in detecting even slightly abnormal structural relationships of joints.^{2, 6, 24, 30} The sense of severe, ill-defined, yet nonpainful apprehension experienced by the subject in this study when the arthroscope was positioned between the patella and trochlea can be interpreted as representing intense proprioceptive output of the knee, stimulating protective neural circuitry and resulting in cerebral perception. We believe the effusion that developed after the procedure on the left knee represented a chemical synovitis caused by the Omnipaque mixture that eventually leaked into the intraarticular environment.

The findings of sensation experienced with palpation of articular cartilage deserve special comment. It is well established by histologic studies that articular cartilage lacks neural elements.¹⁷ This objective microscopic finding explains the lack of perception in palpated patellar articular cartilage. We believe that perception of palpated articular cartilage of the tibial plateaus, femoral condyles, trochlea, and patellar odd facets probably represents sensation arising from transmission of sensory stimulating loads to subchondral bone in these areas of thinner cartilage, rather than from the cartilage per se. The documentation of sensation arising from the intraosseous environment of the knee has been shown in prior work by the first author, where increases in intraosseous pressure caused transient severe pain.^{11, 12} The general absence of patellar articular cartilage sensation noted in the current study provides an explanation for the presence of asymptomatic chondromalacia that is often found at surgery. This observation may provide support for those who question the

causal relationship between the presence of patellar chondromalacia and the occurrence of anterior knee pain. Our present study also confirms the association of asymptomatic chondromalacia and normal technetium scintiscans documented in prior work,^{7, 11, 12} which revealed that homeostasis of the patellar osseous components is possible despite normal age-related structural failure of the articular cartilage.

The results of this subjective study may point to new avenues for research designed to delineate factors that determine, maintain, and restore normal neurosensory characteristics of intraarticular structures of musculoskeletal systems. Such future research may ultimately lead to the development of techniques that result in true restoration of joint homeostasis and function.

ACKNOWLEDGMENTS

The authors recognize the following individuals for their help in the preparation of this work: Gregory W. Allen, CST, Mary S. Shrimpton, RN, William T. Halsey, MD, Jeffrey D. White, MD, Mr. Gregory Monardo, Stephen Follansbee, MD, and William Bieber, MD, of the California Pacific Medical Center, Davies Campus, San Francisco, California; Robert Johnson, MD, and Bruce Beynon, PhD, of the University of Vermont, Burlington, Vermont; Peter Radcliff, PhD, Department of Philosophy, San Francisco State University, San Francisco, California; Mr. Allen Smoot and the Stryker Corporation of America, Santa Clara, California; Ann Dye, RN, Ira Dye, Capt, USN (Retired), Lottie Applewhite, Anne Shew, and Rebecca Larsen.

REFERENCES

- Barrack RL, Lund PJ, Munn BG, et al: Evidence of reinnervation of free patellar tendon autograft used for anterior cruciate ligament reconstruction. *Am J Sports Med* 25: 196-202, 1997
- Barrack RL, Skinner HB, Buckley SL: Proprioception in the anterior cruciate deficient knee. *Am J Sports Med* 17: 1-6, 1989
- Barrett DS, Cobb AG, Bentley G: Joint proprioception in normal, osteoarthritic, and replaced knees. *J Bone Joint Surg* 73B: 53-56, 1991
- Biedert RM, Stauffer E, Friederich NF: Occurrence of free nerve endings in the soft tissue of the knee joint. A histologic investigation. *Am J Sports Med* 20: 430-433, 1992
- Chong A, Bruce W, Goldberg J: Treatment of the neuropathic knee by arthroplasty. *Aust N Z J Surg* 65: 370-371, 1995
- Clark FJ, Horch KW, Bach SM, et al: Contributions of cutaneous and joint receptors to static knee-position sense in man. *J Neurophysiol* 42: 877-888, 1979
- Denti M, Monteleone M, Berardi A, et al: Anterior cruciate ligament mechanoreceptors. Histologic studies on lesions and reconstruction. *Clin Orthop* 308: 29-32, 1994
- Derwin KA, Glover RA, Wojtyls EM: Nociceptive role of substance-P in the knee joint of a patient with congenital insensitivity to pain. *J Pediatr Orthop* 14: 258-262, 1994
- Dye SF: The knee as a biologic transmission with an envelope of function. A theory. *Clin Orthop* 325: 10-18, 1996
- Dye SF: An evolutionary perspective of the knee. *J Bone Joint Surg* 69A: 976-983, 1987
- Dye SF, Boll DA: Radionuclide imaging of the patellofemoral joint in young adults with anterior knee pain. *Orthop Clin North Am* 17: 249-262, 1986
- Dye SF, Chew MH: The use of scintigraphy to detect increased osseous metabolic activity about the knee. *J Bone Joint Surg* 75A: 1388-1406, 1993
- Farsetti P, Caterini R: Idiopathic Charcot's arthropathy. Report of one case. *Arch Orthop Trauma Surg* 111: 282-283, 1992

14. Freeman MA, Wyke B: The innervation of the knee joint. An anatomical and histological study in the cat. *J Anat* 101: 505-532, 1967
15. Gardner E: The innervation of the knee joint. *Anat Rec* 95: 109-130, 1948
16. Grabiner MD, Koh TJ, Draganich LF: Neuromechanics of the patellofemoral joint. *Med Sci Sports Exer* 26: 10-21, 1994
17. Greep R, Weiss L: *Histology*. Third edition. New York, McGraw Hill Book Co, 1973
18. Hirsch E, Moye D, Dimon J III: Congenital indifference to pain: Long term follow-up of two cases. *South Med J* 88: 851-857, 1995
19. Horner G, Dellon AL: Innervation of the human knee joint and implications for surgery. *Clin Orthop* 301: 221-226, 1994
20. Johansson H, Sjölander P, Sojka P: A sensory role for the cruciate ligaments. *Clin Orthop* 268: 161-178, 1991
21. Kimball ES (ed): *Cytokines and Inflammation*. Boca Raton, FL, CRC Press, 1991
22. Koshino T: Stage classifications, types of joint destruction, and bone scintigraphy in Charcot joint disease. *Bull Hosp Jt Dis Orthop Inst* 51: 205-217, 1991
23. Krauspe R, Schmidt M, Schaible H-G: Sensory Innervation of the anterior cruciate ligament. An electrophysiological study of the response properties of single identified mechanoreceptors in the cat. *J Bone Joint Surg* 74A: 390-397, 1992
24. Newton RA: Joint receptor contributions to reflexive and kinesthetic responses. *Phys Ther* 62: 22-29, 1982
25. O'Connor BL, Visco DM, Brandt KD, et al: Neurogenic acceleration of osteoarthritis. The effects of previous neurectomy of the articular nerves on the development of osteoarthritis after transection of the anterior cruciate ligament in dogs. *J Bone Joint Surg* 74A: 367-376, 1992
26. Pitman MI, Nainzadeh N, Menche D, et al: The intraoperative evaluation of the neurosensory function of the anterior cruciate ligament in humans using somatosensory evoked potentials. *Arthroscopy* 8: 442-447, 1992
27. Proske U, Schaible H, Schmidt RF: Joint receptors and kinaesthesia. *Exp Brain Res* 72: 219-224, 1988
28. Schultz RA, Miller DC, Kerr CS, et al: Mechanoreceptors in human cruciate ligaments. A histological study. *J Bone Joint Surg* 66A: 1072-1076, 1984
29. Schutte MJ, Dabezies EJ, Zimny ML, et al: Neural anatomy of the human anterior cruciate ligament. *J Bone Joint Surg* 69A: 243-247, 1987
30. Skinner H, Barrack R: Joint position sense in the normal and pathologic knee joint. *J Electromyogr Kinesiol* 1: 180-190, 1991
31. Warren PJ, Olanlokun TK, Cobb AG, et al: Proprioception after knee arthroplasty. The influence of prosthetic design. *Clin Orthop* 297: 182-187, 1993
32. Wittgenstein L: *Philosophical Investigations*. Anscombe GEM, trans. Third edition. Englewood Cliffs, NJ, Prentice Hall, 1973
33. Yoshino S, Fujimori J, Kajino A, et al: Total knee arthroplasty in Charcot's joint. *J Arthroplasty* 8: 335-340, 1993
34. Zimny ML: Mechanoreceptors in articular tissues. *Am J Anat* 182: 16-32, 1988
35. Zimny ML, Albright DJ, Dabezies E: Mechanoreceptors in the human medial meniscus. *Acta Anat (Basel)* 133: 35-40, 1988

...ous sys
...ly cre
...d a neur
... cases ma
... acute of
... by Barrack
... and inco
... ACL re

U. White, MD, Director
Department of Orthopedic Surgery
Pacific Medical Center, Portland, OR
11111
11111

... is well
... articular cartilage
... find
... patellar
... pated
... tyles
... caused
... patellar
... study
... due

... Surg 33:
... Oct 1995
... 1335