

Operative management of “hockey groin syndrome”: 12 years of experience in National Hockey League players

Kashif Irshad, MD, Liane S. Feldman, MD, Caroline Lavoie, PT, Vincent J. Lacroix, MD, David S. Mulder, MD, and Rea A. Brown, MD, Montreal, Quebec, Canada

Background. At the elite level of hockey, groin injuries can threaten a player’s career. The aim of this review is to describe the clinical presentation and evaluate our operative approach to “hockey groin syndrome” in National Hockey League (NHL) players.

Methods. Between November 1989 and June 2000, 22 NHL players with debilitating groin pain underwent operative exploration. A repair, including ablation of the ilioinguinal nerve and reinforcement of the external oblique aponeurosis with a Goretex (W.L. Gore & Associates, Inc, Flagstaff, Ariz) mesh, was performed. Medical records were reviewed, and the players or their trainers were contacted by telephone after a mean follow-up period of 31.2 months to assess function, symptoms, and overall satisfaction.

Results. All patients had tearing of the external oblique aponeurosis, with branches of the ilioinguinal nerve emerging from the torn areas. At follow-up, 18 players (82%) had no pain, whereas 4 (18%) reported mild, intermittent pain. All 22 patients returned to playing hockey, with 19 (85%) able to continue their careers in the NHL.

Conclusions. The “hockey groin syndrome,” marked by tearing of the external oblique aponeurosis and entrapment of the ilioinguinal nerve, is a cause of groin pain in professional hockey players. Ilioinguinal nerve ablation and reinforcement of the external oblique aponeurosis successfully treats this incapacitating entity. (*Surgery* 2001;130:759-66.)

From the Departments of Surgery, Physiotherapy, and Family Medicine, McGill University, Montreal, Quebec, Canada

THE DIAGNOSIS AND MANAGEMENT of chronic groin pain in athletes can pose a major dilemma. Although groin pain in amateur athletes may be responsible for time away from sport or work, at the elite level of hockey, these injuries can threaten a player’s career. Groin injuries represent a major cause of morbidity among National Hockey League (NHL) players. In 1997, the cumulative incidence rate was 20 groin or abdominal strain injuries per 100 players per year.¹ Although conservative management is often effective, some injuries ultimately necessitate operative repair when other measures fail. We describe a series of 22 NHL players who underwent groin exploration after their injuries did not resolve with conserva-

tive treatment. In these athletes, small tears in the external oblique aponeurosis were found, through which neurovascular bundles containing branches of the ilioinguinal or iliohypogastric nerves emerged. We have dubbed the presentation of groin pain in association with this operative finding *hockey groin syndrome* and have previously reported our experience, with shorter follow-up, in 11 cases.² The aim of this review is to evaluate the clinical outcome of our operative approach to hockey groin syndrome in professional hockey players.

PATIENTS AND METHODS

Between November 1989 and June 2000, 22 NHL players with a mean age of 26 years (range, 20-33 years) were referred to the McGill University Health Centre with groin pain that prevented them from playing hockey and then underwent operative groin exploration. Of the 22 patients, 10 (45%) were forwards and 12 (55%) were defensemen; none were goalies. Eleven patients (50%) had left-sided groin pain, 10 (45%) had right-sided pain, and 1 had bilateral symptoms. Conservative

Presented at the 58th Annual Meeting of the Central Surgical Association, Tucson, Ariz, March 7-10, 2001.

Reprint requests: Liane S. Feldman, MD, Montreal General Hospital, L9-316, 1650 Cedar Ave, Montreal, Quebec, Canada, H3G 1A4.

Copyright © 2001 by Mosby, Inc.

0039-6060/2001/\$35.00 + 0 11/6/118093

doi:10.1067/msy.2001.118093

management, such as physiotherapy, local anesthetic, or steroid injections, failed in all the patients. The mean time from the initial injury to referral was 24 weeks (range, 2-48 weeks).

In all patients, the pain was exacerbated by pushing off their skates or taking a slap-shot. The pain was muscular in nature, of gradual onset, and exacerbated by ipsilateral hip extension and contralateral torso rotation. Many players described the pain as being worse in the morning, specifically when getting out of bed. Players also described an exacerbation of their pain with their golf swing. The majority did not recall a specific initial traumatic event.

Physical examination revealed tenderness in the affected groin in all patients. In 15 patients (68%), the external ring was judged by an experienced examiner to be dilated. Many patients had a palpable gap over the external oblique aponeurosis. This gap is best demonstrated when the involved groin is examined while the supine patient elevates the head or while the patient forcefully flexes the hip against resistance. No patient had a clinically apparent inguinal hernia.

Although the radiologic work-up was not standardized and depended in large part on the referring physician, ultrasound, computed tomography, and magnetic resonance imaging (MRI) findings were consistently negative, except in 1 patient who had a diagnostic MRI that demonstrated the tear in the external oblique aponeurosis. All patients had a nuclear bone scan to assess whether the pain was a result of inflammation of the pubic symphysis. The results of the scan were positive in 3 patients.

Each groin was explored with the patients under general anesthesia and through an inguinal incision (the same method as for standard hernia repair). The operative findings were noted, all perforating neurovascular bundles were excised, the main trunk of the ilioinguinal nerve was ablated, and the external oblique aponeurosis was repaired. In all patients, the nerve was resected with use of electrocautery as far proximally as possible through the inguinal incision. In 19 patients, the external oblique aponeurosis was further reinforced with a Goretex (W.L. Gore & Associates, Inc) mesh. The mesh was secured to the edges of the opened external oblique aponeurosis with 2-0 polypropylene sutures, creating a new anterior inguinal wall. This mesh was placed to reduce tension on the aponeurosis and to prevent regenerating nerve tissue from become entrapped. Three patients did not have a mesh inserted because it was believed that the tears in the external oblique aponeurosis could be repaired primarily without tension. After the oper-

ation, patients underwent a standardized 9-week course of physiotherapy (Table I).

A list of the patients' names who underwent this procedure was kept prospectively. For the purposes of this study, office and hospital records of the NHL players were reviewed to record preoperative symptoms, physical findings, radiologic investigations, operative findings, and pathologic results. To assess outcome, the players or their trainers were contacted by telephone after a mean follow-up period of 31.2 months (range, 2.5-139 months). Function, symptoms, and overall satisfaction were assessed.

RESULTS

At operation, all patients had 1 or more tears in the external oblique aponeurosis, with emergence of branches of the ilioinguinal or iliohypogastric nerves in the torn areas (Fig 1). The tears were in the direction of the fibers of the external oblique aponeurosis, and the lengths ranged from 3 to 12 cm. The perforating neurovascular bundles were excised and sent for pathologic examination. The external oblique aponeurosis was then opened along the direction of its fibers. Exploration of the inguinal canal was undertaken, and no hernias were found. In all patients, the conjoined tendon appeared to be unaffected and the transversalis fascia did not appear to be weakened. A lipoma was excised from the spermatic cord in 4 patients (18%). The ilioinguinal nerve was then identified, isolated, and resected as completely as possible. The nerve or its branches was always trapped in the area of the torn aponeurosis, and it commonly had multiple branches. A Goretex mesh was used to reinforce the aponeurosis in all but 3 patients (Fig 2). On pathologic examination of the excised portion of the nerve, perineural fibrosis was seen in 5 patients (23%).

There were 2 early postoperative complications: 1 seroma and 1 hematoma. Both were treated conservatively and resolved quickly. At follow-up, 18 players (82%) had no pain, whereas 4 (18%) reported mild-but-intermittent pain. All patients returned to playing competitive hockey, with 19 (86%) able to continue their careers in the NHL (Table II). Twenty patients (91%) described their overall satisfaction as excellent. Two patients have had a recurrence of their symptoms. Although the symptoms in 1 patient responded to conservative treatment, the other patient needed reoperation, during which a recurrent tear on the operated side was found. During the player's initial surgery, the tear had been repaired primarily, without mesh. The recurrence occurred after the player was checked into the boards while his skate was wedged in the crack

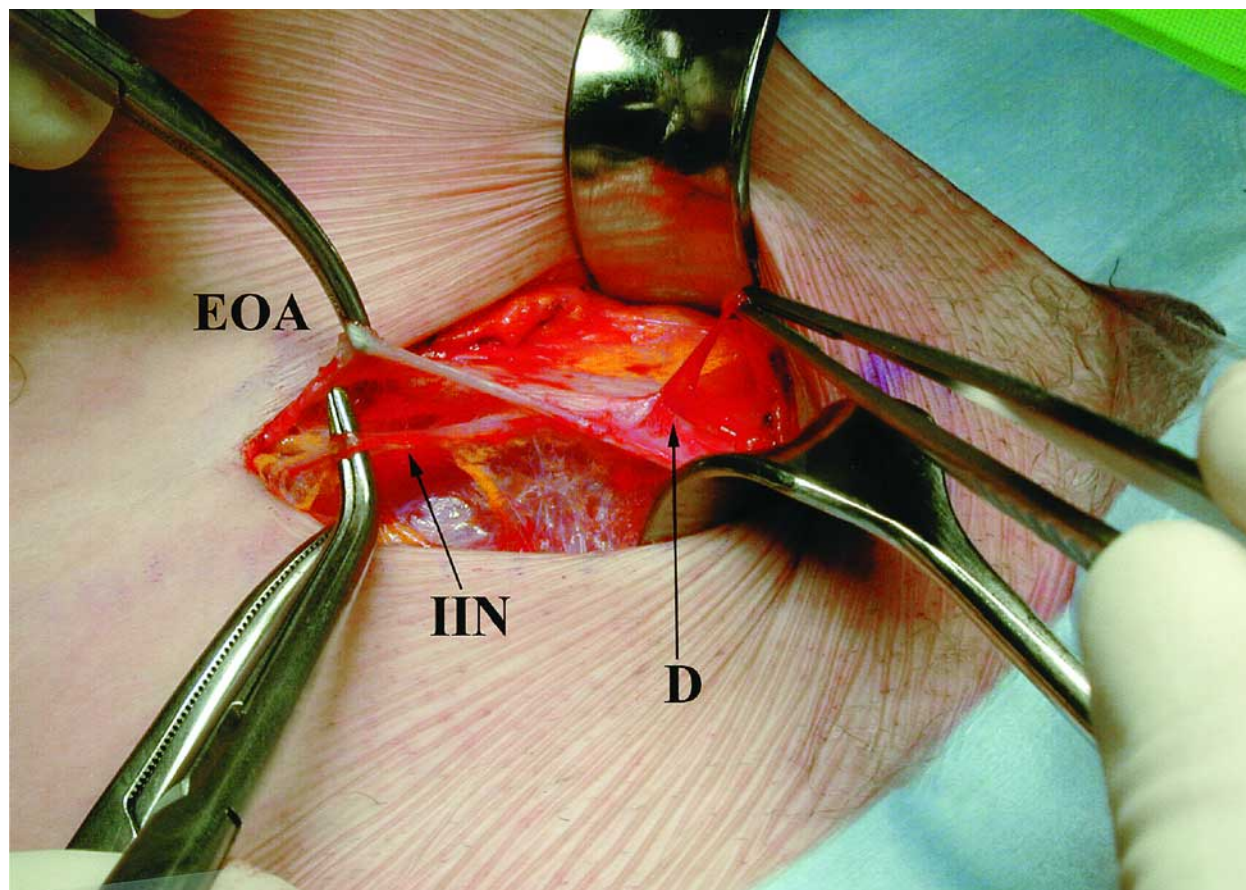


Fig 1. In this patient, right-sided groin exploration revealed a defect in the external oblique aponeurosis (EOA). The distal ilioinguinal nerve (IIN), being held by forceps, protrudes through the defect (D).

Table I. Postoperative recovery program

Time (postoperatively)	Activity
0-48 h	Rest, ice, pain medication
2-7 days	Isometric exercises Abdominal crunches Straight-leg raises Stationary bike
7-28 days	Stabilizing exercises Slow treadmill walks Light squats, exercise ball Stationary bike
4-6 wk	Hockey-specific exercises Easy skating Resisted hip flexion, extension, abduction, and adduction
6-8 wk	Team exercises, on-ice drills
> 8 wk	Return to play

between the ice and the boards. The resulting injury was managed with a mesh that was placed to reinforce the vulnerable external oblique aponeurosis. Both players in whom recurrent symptoms developed have subsequently returned to the NHL.

Table II. Results of operation

Outcome	No.
Pain	
No pain	18
Mild, intermittent pain	4
No improvement in pain	0
Function	
Return to NHL	19
Return to competitive hockey	3
Unable to play competitive hockey	0
Recurrence	2

DISCUSSION

Groin injuries are extremely common in sports that demand sudden muscle contraction around the hip and lower abdomen. Such sports include soccer, skiing, ice hockey, rugby, hurdles, and high jump.⁴ The differential diagnosis of groin pain in the elite athlete is extensive and differs somewhat from that of the general population. However, when examining an athlete with groin pain, one must rule out the more general causes before considering sports-specific injuries. For example,

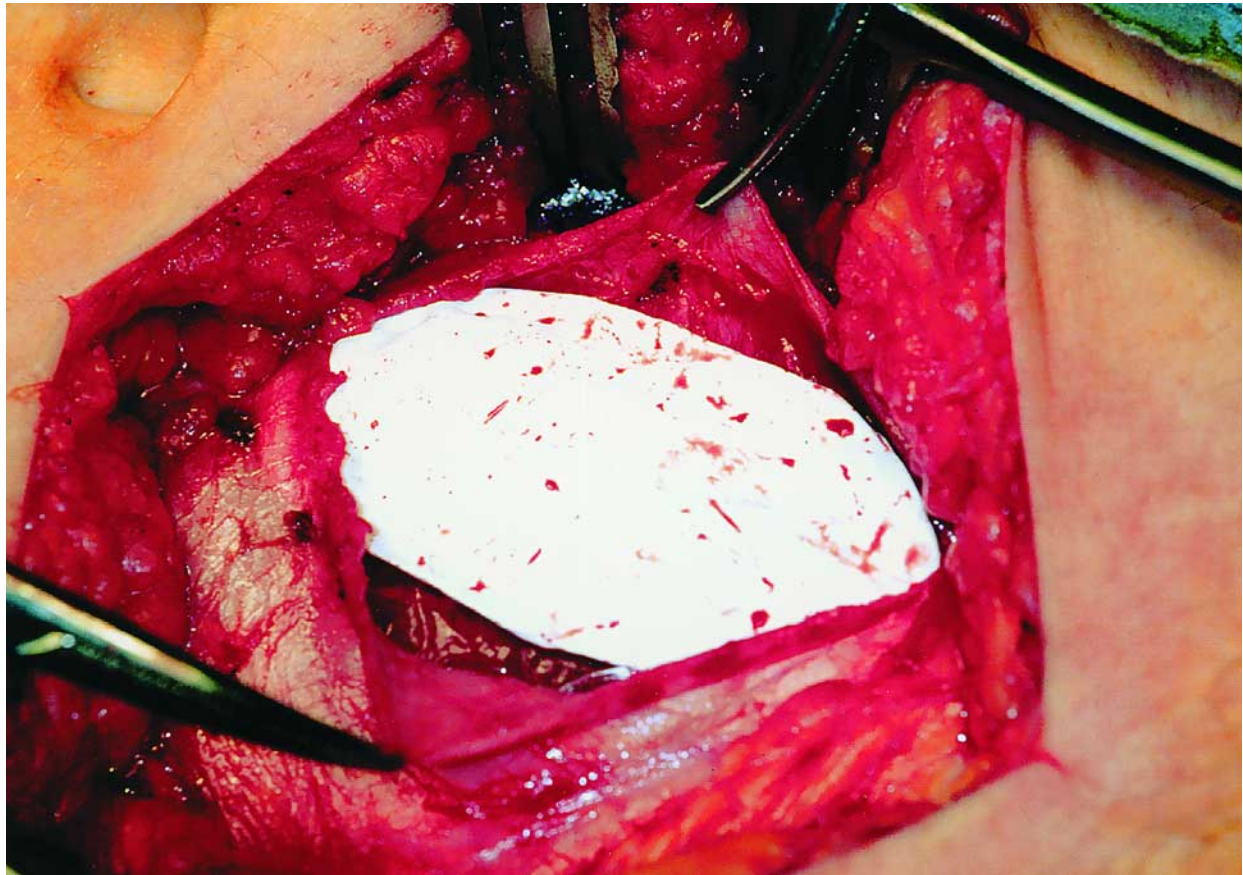


Fig 2. Goretex mesh is placed along the borders of the external oblique aponeurosis and secured in place with a nonabsorbable suture.

abnormalities of the lumbosacral spine or hip joint may be referred to the groin. Urologic or perineal disease may also present with groin pain.⁵ Of course, an inguinal hernia must be excluded with careful physical examination.

Although the classification of causes of groin pain in athletes has been confusing in the past, an increasingly well-defined list of conditions has begun to emerge. A focused history and physical examination are crucial since groin pain may have multiple causes. Some of the common causes of groin pain in athletes include (1) osteitis pubis; (2) muscle or tendon strains, particularly of the adductor longus and the rectus abdominis muscles and the short hip flexors; (3) ilioinguinal neuralgia; and (4) disruption of the inguinal canal with dilatation of the external ring and thinning of the posterior wall (sportsman's hernia). We now add hockey groin syndrome, marked by entrapment of the ilioinguinal nerve branches in tears of the external oblique aponeurosis, to this list.

The diagnosis of hockey groin syndrome is suspected on clinical grounds and confirmed with operative findings. It is important to consider and

try to exclude other causes of groin pain in the athlete before operative exploration. Radiologic investigations have not proved fruitful in diagnosing hockey groin syndrome in most cases.

However, a bone scan is performed in all patients to detect increased uptake in the pubic symphysis, indicating the presence of osteitis pubis. Patients with osteitis pubis also usually have focal tenderness at the pubic symphysis.⁶ Osteitis pubis can be difficult to treat but usually responds to conservative measures. The 3 patients who had a concomitant diagnosis of osteitis pubis had a significantly improved follow-up bone scan. All 3 of these patients are pain free and were able to return to the NHL. The diagnosis of an adductor tendon lesion is eliminated by the absence of pain in the upper thigh and an inability to reproduce the pain with active-resisted hip adduction. Ilioinguinal neuralgia is eliminated by the absence of pain in the iliac fossa region and the lack of tenderness over the lateral abdominal wall, the site where the nerve pierces the abdominal musculature.

Once these possibilities are deemed unlikely, the diagnosis of hockey groin syndrome should be con-

sidered. Commonly, patients with this syndrome have a dilated external ring and a gap that is palpable in the inguinal area, likely representing the tear in the aponeurosis. Patients always undergo a long period of physiotherapy, as reflected in the mean time from symptom onset to referral of about 4 months. The decision to surgically explore the patient is based on the response to physiotherapy. While other causes of groin pain often improve substantially with conservative measures, the nerve entrapment associated with the pain of hockey groin syndrome does not. On the other hand, surgical repair of the tears in the external oblique aponeurosis and resection of the perforating nerve bundles and ilioinguinal nerve trunk allowed all 22 athletes to return to competitive hockey, with most being extremely satisfied with their results.

Disruption of the posterior wall of the inguinal canal (sportsman's hernia) has been reported to be the most common operative finding in patients with chronic groin pain.⁶ We have not found this in our patient population. On the other hand, Gilmore⁷ considers the site of the problem to be the anterior abdominal wall. Gilmore described a triad of operative findings in soccer players who underwent operation for refractory groin pain: torn external oblique aponeurosis, causing external ring dilatation; torn conjoint tendon; and dehiscence between the inguinal ligament and conjoint tendon. Some of our findings overlap with these, although the conjoint tendon and inguinal ligament remained intact. All of our patients had involvement of the ilioinguinal nerve, which we believe plays an important role in the patient's debilitating symptoms. Direct trauma to this nerve, intense abdominal muscle training, or other inflammatory conditions could lead to entrapment of the nerve as it passes through the abdominal muscle layers,² leading to this discomfort. Several other potential mechanisms have been suggested to explain why the incidence of this condition seems to be increasing (Linden, personal communication, February 2001). The slap-shot may be largely responsible because of the significant force that is transmitted to the abdominal wall when the heel of the hockey stick hits the ice surface. This force may be compounded by the shafts of hockey sticks that are now reinforced with rigid and unforgiving materials such as metal and fiberglass. This may explain why this syndrome does not affect players who do not have to take slap-shots, such as goaltenders. Also, the newer designs of hockey skates have not only allowed players to skate faster but have made players more vulnerable to injury. The boot is rigid, allowing for little flexibili-

ty when a poorly positioned player is checked. This may place significant stress on the abdominal wall during sudden changes in direction.

There has been an increasing emphasis on strength training among hockey players. It was noted that all 22 players had significantly hypertrophied internal oblique muscles, perhaps placing a shearing force on the external oblique aponeurosis, contributing to the fascial tears or thinning (Finley, personal communication, February 2001).

Even though ilioinguinal nerve entrapment is a well-known cause of chronic groin pain among patients with previous lower abdominal surgery (eg, appendectomy or inguinal herniorrhaphy), only 4 patients in our series had a history of undergoing such procedures.

Our findings are similar to those reported by Ziprin et al,³ in which 25 male athletes, mainly soccer players, underwent groin exploration after nonoperative management failed. In these patients, defects were found in the external oblique aponeurosis, through which neurovascular bundles passed. After division of these bundles and primary repair of the tears in the aponeurosis, no pain or only mild pain was experienced in all but 1 groin. The mechanism of injury of the soccer players may be similar to that of hockey groin syndrome. The soccer kick transmits a significant amount of explosive force to the abdominal wall, similar to the slap-shot.

Because this is a preliminary report, with no control group, we cannot conclude with certainty that the operation along with physiotherapy is better than physiotherapy alone. However, the fact that all players received long courses of preoperative physiotherapy with little improvement supports the potential benefits of an operative intervention. In addition, the group of patients in this study represents an extremely motivated cohort, and it is not certain that these gratifying results can be expected in nonelite athletes.

Postoperative follow-up was difficult because the players frequently lived in other cities. It was obtained through close contact with personal trainers and players, who were informed about clinical signs of recurrence. Although not ideal for an unbiased assessment of subtle symptom recurrences, this method allowed for follow-up regarding return to play.

In summary, the hockey groin syndrome, marked by tearing of the external oblique aponeurosis that involves branches of the ilioinguinal nerve, is a cause of groin pain in professional hockey players. The difficulty in making the diagnosis and the paucity of knowledge about this pain syn-

drome lead to unnecessary delays in diagnosis. History and physical examination are suggestive, and radiologic investigations are rarely helpful. When conservative measures fail, groin exploration with ilioinguinal nerve ablation and reinforcement of the external oblique aponeurosis can be used to successfully treat this incapacitating entity.

The authors thank Mr Trevor Linden, President of the NHL Players' Association, and Dr John Finley, Physician-in-Chief of the Detroit Red Wings, for their comments in the preparation of this manuscript.

REFERENCES

1. Emery CA. Groin and abdominal strain injuries in the National Hockey League. *Clin J Sport Med* 1999;9:151-6.
2. Lacroix VJ, Kinnear DG, Mulder DS, Brown RA. Lower abdominal pain syndrome in National Hockey League players: a report of 11 cases. *Clin J Sport Med* 1998;8:5-9.
3. Ziprin P, Williams P, Foster ME. External oblique aponeurosis nerve entrapment as a cause of groin pain in the athlete. *Br J Surg* 1999;86:566-8.
4. Renstrom PAFH, Peterson L. Groin injuries in athletes. *Br J Sports Med* 1980;14:30-6.
5. MacLeod DAD, Gibbon WW. The sportsman's groin. *Br J Surg* 1999;86:849-50.
6. Fon LJ, Spence RAJ. Sportsman's hernia. *Br J Surg* 2000;87:545-52.
7. Gilmore OJA. Ten years experience of groin disruption: a previous unsolved problem in sports medicine. *Sports Med Symposium, Pfizer Institute; Edinburgh (UK): March 1991.*

DISCUSSION

Dr L. Michael Brunt (St Louis, Mo). I would like to congratulate the authors on their paper. I enjoyed it very much and appreciate the opportunity to have reviewed the manuscript in advance.

The problem with chronic activity limiting groin pain, or so-called athletic pubalgia in elite level athletes—not just hockey players, but a lot of different athletes—is an important one. This is something that has received increased attention in sports medicine circles in recent years.

I must confess that the first time that I was asked to see one of our NHL players with groin pain several years ago, I was skeptical about the role of surgical intervention in treating this problem. However, thanks to the Montreal group, as well as others who have written about this problem, and my own experience with our local NHL players and other athletes, I can assure you this is a very real problem. In the NHL, as the authors have pointed out, it is a major source of time lost to injury, and there is clearly a subset of athletes who fail conservative therapy and in whom surgery offers the only chance to return to competitive play. So I would like to congratulate you for bringing this to the attention of the general surgical community, since virtually everything written on this topic to date has been in the sports medicine literature.

Still, this is a difficult group for many reasons, including the absence of any specific diagnostic tests; subtle exam findings; and to a large extent, as you pointed out, it is a diagnosis of exclusion, and therefore selection of

patients for operation is difficult but also critical to a successful outcome. Obviously there is a lot of pressure on having successful outcomes in this group. I have a few questions for you.

First, when do you decide to operate? How long of a period of conservative therapy before you would recommend surgical repair? And what were the key findings that confirmed the diagnosis? What radiologic tests do you now do? Only an MRI? You have to do some tests to exclude other diagnoses.

Since most general surgeons will not be taking care of NHL players, what is your experience in treating other athletes with chronic groin pain? And have you started to see this in any elite female athletes?

Thirdly, others have reported more variable operative findings in hockey players—this mirrors somewhat my own experience—especially a weakened or torn inguinal floor that is virtually absent in a very attenuated fashion.

Is nerve entrapment in the external oblique the only explanation for the pain? Of the 4 patients you had with persistent pain, did they have neurolysis? If they did, what do you think the basis was for their recurrent pain?

Do you always resect the ilioinguinal nerve as it exits the internal ring? What about the iliohypogastric nerve? Do you do anything with that? As you pointed out, some of these players have a component of medial thigh pain or adductor involvement. Do you approach these individuals any differently? Do you think there is any role for adductor release in managing these patients?

In regard to your operative technique, is the mesh repair you do the same as you would do for an inguinal hernia repair, or do you modify your mesh placement somewhat? And why Goretex and not polypropylene?

Then finally, you commented that you did these all under spinal or general anesthesia. My preference has been to do them under local anesthesia with sedation. So I think that is also an alternative anesthetic for these patients.

Dr Roland Vega (Madison, Wis). For anyone who has had kids who played hockey, you know that the quandary over the length of one's stick and whether it should come to one's chin or one's nose or top of one's head is often debated, depending upon who is coaching you at the time. Since the slap-shot itself seems to somehow play a role, whether you have looked at height ratios in these people.

The other thing is that this is becoming an increasing problem. Hockey used to be a small man's game and is now, especially in the NHL, becoming a very large man's game. Is the size of the athlete an issue here as you look across the NHL, and which subset is more susceptible to these things?

Dr James R. Starling (Madison, Wis). I am anxious to read your paper and especially look at your references. When I read the title of your talk, I said to myself: What they are talking about is pubalgia.

Pubalgia is a rare diagnosis, which has been written about in the 80s and early 90s, mainly in soccer players. The recommended operation for chronic pubalgia in soccer players is not to take the ilioinguinal nerve or use mesh, but simply to do a modified Bassini operation with

a relaxing incision of the internal oblique aponeurosis. If you look at this literature and if you look at my experience taking care of high-profile athletes with groin pain, the results are similar.

So I question whether or not one needs to put in mesh in these patients in this era of “meshomania” or the necessity to resect the ilioinguinal nerve. Maybe you can simply do a neurolysis and fix the defect.

Dr Michael S. Nussbaum (Cincinnati, Ohio). In your follow-up of these athletes, have there been any long-term sequela related to the neurolysis? Do these athletes complain of any difficulties in terms of pain or numbness over the long term?

Is this abnormality amenable to a laparoscopic or preperitoneal laparoscopic approach? It looks like you are placing the mesh just underneath the external oblique. How do you actually place the mesh and what do you attach it to? Could the mesh be placed via a minimally invasive approach in a preperitoneal position, and could you perform the neurolysis from an extraperitoneal approach?

Dr John L. Butsch (Buffalo, NY). I want to thank you very much for allowing me to make a comment on your paper, Dr Irshad, and I compliment you for your excellent presentation. I would like to ask you 2 questions. The other questions have already been asked.

Have you tried to do a local anesthetic field block in order to shorten the time from the onset of symptoms to your surgical procedure? If the pain is relieved, you might make an earlier diagnosis. Then the player would be able to return to the rink sooner because he had a quicker operation.

I would like to know how you could persuade the hockey players, and especially the management, to have a certain number of the players sit for 4 months as controls while their colleagues are undergoing these surgical procedures for relief of the pain.

Dr Jeremiah G. Turcotte (Ann Arbor, Mich). Hockey is a very major sport in our area. Detroit is frequently referred to as a hockey town. So I thought I would ask the Detroit Red Wings players if they are ever bothered with such injuries. They said they never see this in Detroit. They said our players are always skating towards the goal, not the other direction!

In the Ann Arbor area with a population of 350,000, there are some 60 junior league hockey teams. So more seriously, I wonder if you would comment on the age distribution of this injury. Is this something that is confined to adults or professional players, or does it occur in all ages?

Dr Brown. All the questions and comments about this paper have been asked by myself many, many times, as I have seen these professional athletes presenting in my office. When the first case came, I did a nice history and physical examination. As Dr Irshad has pointed out, I was left with no physical findings, and all modern radiological investigations were negative. The player couldn't play professional hockey after prolonged physical therapy and the use of all prescribed medications because of severe pain in the groin area above the inguinal ligament.

I reviewed all the North American literature to find no help. In British surgical literature, professional soccer players with a similar problem as this hockey player have been successfully operated on. I changed from an aggressive surgeon to a timid one. I, personally, have operated on all of the players presented in this paper. Fortunately, I had Dr David Mulder to consult with prior to the decision of surgery being made. In our country (Canada), nobody knows more about hockey players' injuries than Dr Mulder.

A bone scan is the only necessary test to be done after routine blood work. All of the modern radiologic investigative tools have failed to detect a tear. There was only 1 positive MRI.

Nine weeks of conservative therapy is required before surgery is performed. In this special group of athletes, if they cannot return to full game action by 9 weeks, they need surgery. In the nonprofessional athlete, you will go (wait) longer if the symptoms are improving. If the symptoms are the same or more severe at 9 weeks, I feel surgery is indicated.

The tear extends proximal in the external oblique fascia. When the ring is opened, as in an open inguinal hernia technique, a gap will appear approximately 2.5 cm with the nerve often under tension. Routine pathological studies of the nerve shows damage in the nerve. The conjoint tendon and the post wall and floor of the inguinal canal are normal, and the internal oblique muscle is very large. A piece of Goretex mesh is sutured to the under-surface of the external oblique fascia, anterior to the cord, reconstituting the integrity of the external oblique and the external inguinal ring.

Abductor tendon release is done by some surgeons. It was felt that the old hockey player groin injury was related to this muscle and its attachment. We are uncomfortable doing this and have not done it.

As mentioned by the surgeon in Wisconsin, this problem was known to affect soccer players before it appeared in professional hockey players. Surgery, as I can deduce, is not dissimilar to our procedure, but they do not ablate the nerve.

Dr Turcotte, in response to your statement that you had not seen this syndrome in Michigan. Two of the players in this series are prominent members of the Detroit Red Wings. Recently, I was consulted on a 15-year-old boy playing elite hockey in Detroit. He was suffering from this problem. It is not common, but it appears everywhere hockey is played.

All of the players were incapable of playing professional hockey at the level they had established in their short career. The majority were totally incapacitated and, in spite of all modern physiotherapy practices employed, their competitive physical complement was slipping away.

In spite of all tests and many medical options, no solid diagnosis could be made. The players, as well as the coach and general manager, know the next stop is to be demoted to the minors and the end of the NHL career. In each athlete, this is a huge mental stressor, and they have great motivation to get better.

Dr Butsch—local anesthesia for diagnosis and surgery. This is a test that Dr Mulder has used to get pos-

itive diagnosis in a few of our local players. If the player can skate and do all the physical things he needs to do without pain when injected, and if the pain returns to its previous intensity so they cannot after the injection wears off, this is a positive test. All players with a positive test were operated on and operative findings of external oblique tear and nerve entrapment. I do not use local anesthesia for surgery, as the nerve can be very difficult to find. In 2 patients, it took over 30 minutes to find the nerve in a virgin operative field.

The ordinary athlete of all ages is an interesting challenge. In spite of the same good symptoms and operative pathology as the professional athlete, the results are not as good. Any patient on compensation must be carefully assessed and surgery deferred. Professional football players, soccer, and high-level swimmers have all done well and returned to full activity in their sport. In conclusion, the syndrome of hockey player's groin is a clinical diagnosis. In this group of professional hockey players, all returned to their previous level of competition after surgery.