

Biceps Load Test II: A Clinical Test for SLAP Lesions of the Shoulder

Seung-Ho Kim, M.D., Ph.D., Kwon-Ick Ha, M.D., Ph.D., Jin-Hwan Ahn, M.D., Ph.D., Sang-Hyun Kim, M.D., and Hee-Joon Choi, M.D.

Purpose: The purpose of this report is to describe the biceps load test II for evaluating the superior labral anterior and posterior (SLAP) lesions. **Type of Study:** This is a double-blind study in consecutive data, which includes diagnostic accuracy of a test using sensitivity, specificity, and interexaminer reliability. **Methods:** In the supine position, the arm is elevated to 120° and externally rotated to its maximal point, with the elbow in the 90° flexion and the forearm in the supinated position. The patient is asked to flex the elbow while resisting the elbow flexion by the examiner. The test is considered positive if the patient complains of pain during the resisted elbow flexion. The test is negative if pain is not elicited or if the pre-existing pain during the elevation and external rotation of the arm is unchanged or diminished by the resisted elbow flexion. A prospective study was performed in 127 patients to evaluate the diagnostic accuracy for the biceps load test II. Two independent examiners were assigned to perform the new diagnostic test. The results of the tests were confirmed during the arthroscopic examination. **Results:** A positive test result in 38 subjects correlated with a SLAP lesion in 35 patients and an intact biceps-superior labrum in 3 patients. A negative test result in 89 patients correlated with an intact superior labrum complex in 85 patients, whereas 4 patients with a negative test result had a type II SLAP lesion. The biceps load test II had a sensitivity of 89.7%, a specificity of 96.9%, a positive-predictive value of 92.1%, a negative-predictive value of 95.5%, and a kappa coefficient of 0.815. The abduction and external rotation of the shoulder during the test changes the relative direction of the biceps fiber in a position of oblique angle to the posterosuperior labrum. The resisted contraction of the biceps increases the pain generated on the superior labrum that is already peeled off the glenoid margin in the abducted and externally rotated position. **Conclusions:** The biceps load test II is an effective diagnostic test for SLAP lesions. **Key Words:** SLAP lesion—Biceps load test II—Shoulder.

Since the description of the superior labral lesions in throwing athletes by Andrew et al.¹ and the introduction of the acronym SLAP (superior labrum anterior and posterior) lesion by Snyder et al.,² the role of this biceps–superior labral complex in the shoulder

mechanism has become better understood. An increasing number of publications have focused on the anatomy, function, diagnosis, and results of treatment.³⁻¹³ However, the symptoms and signs of the SLAP lesions are often ill defined. Although several physical examinations for SLAP lesions have been described, differential diagnosis between the SLAP lesion and rotator cuff impingement or acromioclavicular joint abnormalities are not easy with the clinical presentation of the patients.^{7,14-17}

Our department had reported a new diagnostic test (biceps load test of Kim) for SLAP lesions in shoulders with recurrent anterior dislocation.¹⁸ As a continuum to this test, we have developed a new physical examination for isolated SLAP lesions of the shoulder. The purpose of the present study is to describe

From the Department of Orthopaedic Surgery, Sungkyunkwan University School of Medicine, Samsung Medical Center; and Sungkyunkwan University, Sports Medicine Institute, Seoul, Korea.

Address correspondence and reprint requests to Seung-Ho Kim, M.D., Ph.D., Department of Orthopaedic Surgery, Sungkyunkwan University School of Medicine, Samsung Medical Center, 50 Ilwon-Dong, Kangnam-Ku, Seoul 135-710, Korea. E-mail: smcknot@hotmail.com

© 2001 by the Arthroscopy Association of North America
0749-8063/01/1702-2408\$35.00/0
doi:10.1053/jars.2001.20665

this new diagnostic test for isolated SLAP lesions of the shoulder. The test was named biceps load test II as a counterpart of the original biceps load test for SLAP lesions in shoulders with recurrent anterior dislocation.

METHODS

A prospective study was performed in 127 patients to evaluate the diagnostic accuracy for the biceps load test II. Of the 127 patients, 89 were men and 38 women, with the average age being 30.6 years (range, 15 to 52 years). Ninety-one patients (71.7%) had a dominant shoulder involved and 36 (28.3%) were involved in athletic activities such as baseball, tennis, basketball, soccer, volleyball, and swimming. The patients were experiencing shoulder pain and underwent arthroscopic examination during the surgery. Patients with a history of either a shoulder dislocation or a stiff shoulder were excluded from the study. Two independent examiners with no knowledge of the results of the other clinical, radiographic, and magnetic resonance imaging data were assigned to perform the new diagnostic test. The results of the tests were confirmed during the arthroscopic examination.

Biceps Load Test II

The test is conducted with the patient in the supine position. The examiner sits adjacent to the patient on the same side as the shoulder and grasps the patient's wrist and elbow gently. The arm to be examined is elevated to 120° and externally rotated to its maximal point, with the elbow in the 90° flexion and the forearm in the supinated position. The patient is asked to flex the elbow while resisting the elbow flexion by the examiner (Fig 1). The test is considered positive if the patient complains of pain during the resisted elbow flexion and also considered positive if the patient complains of more pain from the resisted elbow flexion regardless of the degree of pain before the elbow flexion maneuver. The test is negative if pain is not elicited by the resisted elbow flexion or if the pre-existing pain during the elevation and external rotation of the arm is unchanged or diminished by the resisted elbow flexion.

Statistics

The reliability of the biceps load test II was evaluated by determining its accuracy and reproducibility. The test's accuracy was assessed by using the predictive value, sensitivity, and specificity. The reproduc-

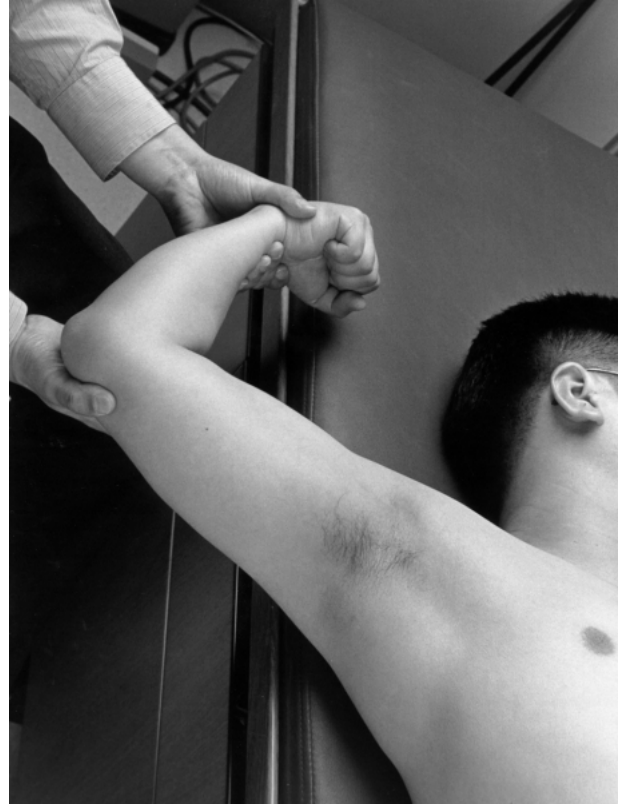

FIGURE 1. Biceps load test II. The arm to be examined is elevated to 120° and externally rotated to its maximal point, with the elbow in the 90° flexion and the forearm in the supinated position. The patient is asked to flex the elbow while resisting the elbow flexion by the examiner.

ibility of the test was assessed by comparing the test results of 2 independent examiners. The kappa coefficient was used to determine the interobserver variation of the 2 examiners. The SPSS program (SPSS, Chicago, IL) was used for all analysis, with the statistical significance level set at $P = .05$.

RESULTS

Of the 127 shoulders, the biceps load test II was positive in 38 and negative in 89. The arthroscopic examination revealed type II SLAP lesions in 39 shoulders. Of the 38 shoulders with a positive test result, 35 had a type II SLAP lesion while the other 3 had an intact superior labrum. Of the 89 shoulders with a negative test result, 4 had type II SLAP lesions, whereas the other 85 shoulders had other abnormalities such as subacromial impingement or a rotator cuff tear. The accuracy of the biceps load test II regarding the detection of the type II SLAP lesion was revealed

with a sensitivity of 89.7%, a specificity of 96.6%, a positive-predictive value of 92.1%, and a negative-predictive value of 95.5%. The kappa coefficient for the interexaminer reliability was 0.815 (Table 1).

DISCUSSION

The biceps–superior labral complex is recognized as a central part of the shoulder mechanism.^{4,9,11,13} Because this complex has an important role in the stabilizing function of the glenohumeral joint, proper diagnosis of the lesion is considered critical for appropriate treatment. However, an accurate clinical diagnosis of the SLAP lesion can be difficult. Although several testing procedures have been developed to evaluate the SLAP lesion, none can be considered completely predictive, nor have any of these tests ever been documented in regard to the biomechanical basis of the tests.^{1,15-17}

A clinical test for SLAP lesions in shoulders with recurrent anterior dislocation, the biceps load test of Kim, has been reported as a dynamic test that is a function of the intact biceps–superior labral complex and explained by the 3 mechanisms.¹⁸ Contraction of the biceps muscle against resistance in the abducted and externally rotated position eliminates the standard apprehension of patients with unstable shoulders with the intact biceps–superior complex, because of partial head reduction by the concavity compression mechanism, internal rotation force, and load-sharing function of the biceps–superior labral complex.¹⁸

The biceps load test II is slightly different from the original biceps load test of Kim (biceps load test I) in terms of the position of the arm and definition of a positive test. Rodosky et al.¹³ reported that abduction and external rotation of the shoulder during the cocking phase of the throwing stresses the origin of the long head of the biceps tendon and its attachment to the posterior labrum. Glousman et al.¹⁹ also demon-

strated in their dynamic electromyographic studies that the biceps is extremely active in throwing athletes when the shoulder is placed in an abducted and externally rotated position. During the biceps load test II, an active contraction of the biceps against resistance further stresses the attachment of the biceps superior labral complex, by which the pain is elicited in the shoulder with the type II SLAP lesion. Furthermore, the biceps load test II can be explained by the recent biomechanical experiment by Kuhn et al.²⁰ In the cadaveric study, the biceps–superior labral complex failed under significantly less force for the maximal cocking position with the arm in 125° of external rotation, 60° of glenohumeral abduction, and in the scapular plane, than in the early deceleration position with the arm in 10° of internal rotation, 60° of glenohumeral abduction, and in 16° of horizontal adduction. They also observed that type II SLAP lesions occurred more frequently in the maximal cocking position. This study suggests that the position of the biceps tendon during load application is a critical component to the pathogenesis of type II SLAP lesions. Because the position of the shoulder during the biceps load test II is the same as that of this biomechanical study, it can be assumed that the biceps load test II reproduces the mechanism in the development of type II SLAP lesions. The biceps load test II can also be reproduced during the arthroscopic examination. As was reported by Burkhart as a peel-back mechanism,²¹ abduction and external rotation of the humeral head displaces the unstable biceps–superior labral complex away from the glenoid margin during the arthroscopic examination. We believe that because the elbow is fixed in the flexed position, the pain in the shoulder with a positive biceps load test II is elicited by the forceful traction of this displaced biceps–superior labral complex during the active contraction of the biceps muscle against resistance (Fig 2).

The fibers of the biceps tendon blend with the large portion of the posterosuperior labrum. The direction of the biceps tendon fibers is parallel to that of the posterosuperior labrum.^{5,8} It would seem that glenohumeral positions that place the biceps in a position different than the orientation of the fibers that comprise the biceps–superior labral complex may increase the likelihood of failure. The abduction and external rotation of the shoulder during the biceps load test II changes the relative direction of the biceps fiber in a position that is of an oblique angle to the posterosuperior labrum. This change in the vector of the biceps force increases the pain generated on the superior labrum that is peeled off the glenoid margin during the

TABLE 1. Statistical Analysis of the Interobserver Reliability of the Biceps Load Test II

	Examiner II*		Total
	Positive	Negative	
Examiner I*			
Positive	34	4	38
Negative	6	83	89
Total	40	87	127

* Kappa value of crosstab between examiner I and II was 0.815.

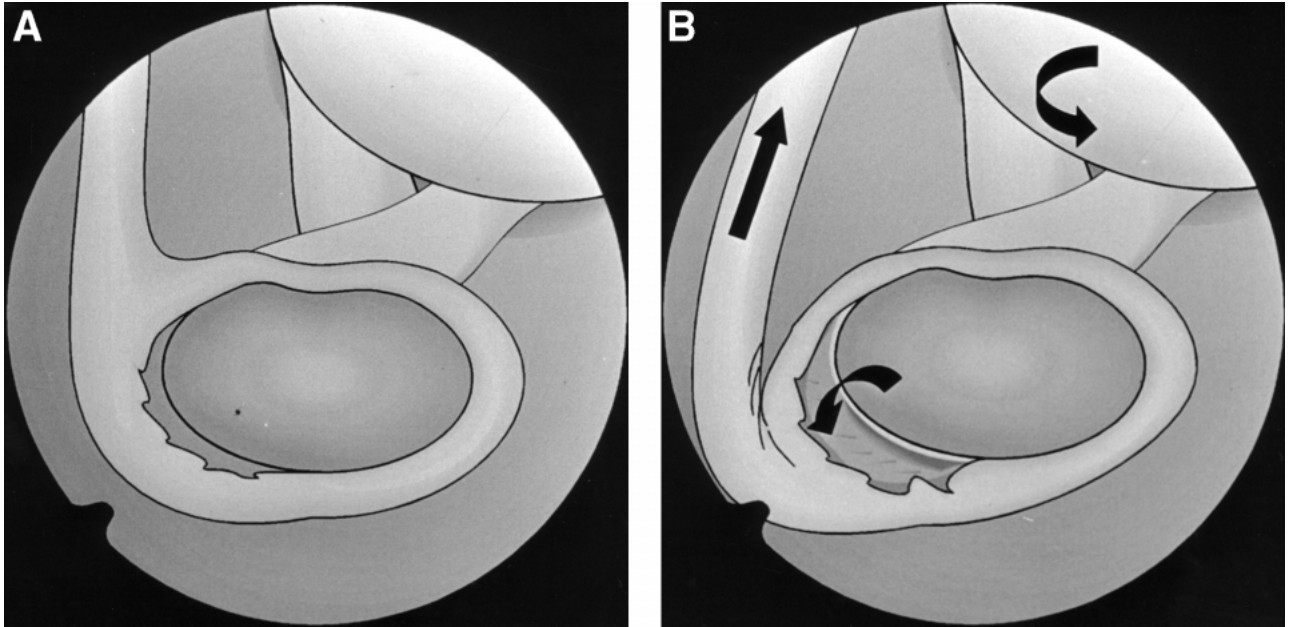


FIGURE 2. (A) In the neutral rotation position of the shoulder, the biceps tendon is parallel to the posterosuperior labrum. (B) The abduction and external rotation of the shoulder during the biceps load test II changes the relative direction of the biceps fiber in a position that is of an oblique angle to the posterosuperior labrum. This change in the vector of the biceps force increases the pain generated on the superior labrum that is peeled off the glenoid margin during the resisted contraction of the biceps in the abducted and externally rotated position.

resisted contraction of the biceps in the abducted and externally rotated position.

The biceps load test II is very sensitive and specific for SLAP lesions and has high positive- and negative-predictive values. Like the original biceps load test of Kim (biceps load test I), the biceps load test II also has high reproducibility between examiners, which is represented by the high kappa coefficient. In conclusion, the biceps load test II is an effective diagnostic test for shoulders with SLAP lesions that is supported by the proven biomechanical mechanism and is demonstrable during the arthroscopic surgery.

Acknowledgment: The authors gratefully appreciate Dr. Kay-Hyun Park for his work in the area of graphics in this study.

REFERENCES

1. Andrews JR, Carson WG, McLeod WD. Glenoid labrum tears related to the long head of the biceps. *Am J Sports Med* 1985;13:337-341.
2. Snyder SJ, Karzel RP, Del Pizzo W, Ferkel RD, Friedman MJ. SLAP lesions of the shoulder. *Arthroscopy* 1990;6:274-279.
3. Altchek DW, Warren RF, Wickiewicz TL, Ortiz G. Arthroscopic labral debridement: A three-year follow-up study. *Am J Sports Med* 1992;20:702-706.
4. Bey MJ, Elders GJ, Huston LJ, Kuhn JE, Blasler RB, Soslosky LJ. The mechanism of creation of superior labrum, anterior, and posterior lesions in a dynamic biomechanical model of the shoulder: The role of inferior subluxation. *J Shoulder Elbow Surg* 1998;7:397-401.
5. Cooper DE, Arnoczky SP, O'Brien SJ, Warren RF, DiCarlo E, Allen AA. Anatomy, histology, and vascularity of the glenoid labrum: An anatomical study. *J Bone Joint Surg Am* 1992;74:46-52.
6. Cordasco FA, Steinman S, Flatow EL, Bigliani LU. Arthroscopic treatment of glenoid labral tears. *Am J Sports Med* 1993;21:425-431.
7. Field LD, Savoie FH III. Arthroscopic suture repair of superior labral detachment lesions of the shoulder. *Am J Sports Med* 1993;21:783-790.
8. Huber WP, Putz RV. Periarticular fiber system of the shoulder joint. *Arthroscopy* 1997;13:680-691.
9. Kumar VP, Satku K, Balasubramaniam P. The role of the long head of biceps brachii in the stabilization of the head of the humerus. *Clin Orthop* 1989;224:172-175.
10. Maffet MW, Gartsman GM, Moseley B. Superior labrum-biceps tendon complex lesions of the shoulder. *Am J Sports Med* 1995;23:93-98.
11. Pagnani MJ, Deng X-H, Warren RF, Torzilli PA, Alchek DW. Effect of superior portion of the glenoid labrum on glenohumeral translation. *J Bone Joint Surg Am* 1995;77:1003-1010.
12. Pagnani MJ, Speer KP, Altchek DW, Warren RF, Dines DM. Arthroscopic fixation of superior labral lesions using a biodegradable implant: A preliminary report. *Arthroscopy* 1995;1:194-198.
13. Rodosky MW, Harner CH, Fu FH. The role of the long head of the biceps muscle and superior glenoid labrum in anterior stability of the shoulder. *Am J Sports Med* 1994;22:121-130.
14. Berg EE, Ciullo JV. A clinical test for superior glenoid labral or SLAP lesions. *Clin J Sport Med* 1998;8:121-123.

15. Kibler WB. Specificity and sensitivity of the anterior slide test in throwing athletes with superior glenoid labral tears. *Arthroscopy* 1995;11:296-300.
16. Liu SH, Henry MH, Nuccion SL. A prospective evaluation of a new physical examination in predicting glenoid labral tears. *Am J Sports Med* 1996;24:721-725.
17. O'Brien SJ, Pagnani MJ, Fealy S, McGlynn SR, Wilson JB. The active compression test for diagnosing labral tears and acromioclavicular joint abnormality. *Am J Sports Med* 1998; 26:610-613.
18. Kim S-H, Ha K-I, Han K-Y. Biceps load test. A clinical test for SLAP lesions in the shoulders with recurrent anterior dislocation. *Am J Sports Med* 1999;27:300-303.
19. Glousman R, Jobe FW, Tibone JE, Moynes D, Antonelli DJ, Perry J. Dynamic electromyographic analysis of the throwing shoulder with glenohumeral instability. *J Bone Joint Surg Am* 1988;70:220-226.
20. Kuhn JE, Lindholm SR, Huston LJ, Soslosky LJ, Blasier RB. Failure of biceps superior labral complex in the throwing athlete: A biomechanical model comparing maximal cocking to early deceleration. Presented at the Annual Meeting of the American Academy of Orthopaedic Surgeons, AANA Specialty Day, Anaheim, CA, February 1999.
21. Burkhart SS, Morgan CD. The peel-back mechanism: Its role in producing and extending posterior type II SLAP lesions and its effect on SLAP repair rehabilitation. *Arthroscopy* 1998;14: 637-640.