

AUTOLOGOUS CHONDROCYTE IMPLANTATION COMPARED WITH MICROFRACTURE IN THE KNEE

A RANDOMIZED TRIAL

BY GUNNAR KNUTSEN, MD, LARS ENGBRETSSEN, MD, PHD, TOM C. LUDVIGSEN, MD,
JON OLAV DROGSET, MD, TORBJØRN GRØNTVEDT, MD, PHD, EIRIK SOLHEIM, MD, PHD, TORBJØRN STRAND, MD,
SALLY ROBERTS, PHD, VIDAR ISAKSEN, MD, AND ODDMUND JOHANSEN, MD, PHD

Investigation performed at University Hospital Tromsø, Tromsø, Oslo Orthopaedic University Clinic, University Hospital Trondheim, Trondheim, Deaconess University Hospital Bergen, Bergen, Norway, and Robert Jones and Agnes Hunt Orthopaedic Hospital, Shropshire, United Kingdom

Background: New methods have been used, with promising results, to treat full-thickness cartilage defects. The objective of the present study was to compare autologous chondrocyte implantation with microfracture in a randomized trial. We are not aware of any previous randomized studies comparing these methods.

Methods: Eighty patients without general osteoarthritis who had a single symptomatic cartilage defect on the femoral condyle in a stable knee were treated with autologous chondrocyte implantation or microfracture (forty in each group). We used the International Cartilage Repair Society, Lysholm, Short Form-36 (SF-36), and Tegner forms to collect data. An independent observer performed a follow-up examination at twelve and twenty-four months. Two years postoperatively, arthroscopy with biopsy for histological evaluation was carried out. The histological evaluation was done by a pathologist and a clinical scientist, both of whom were blinded to each patient's treatment.

Results: In general, there were small differences between the two treatment groups. At two years, both groups had significant clinical improvement. According to the SF-36 physical component score at two years postoperatively, the improvement in the microfracture group was significantly better than that in the autologous chondrocyte implantation group ($p = 0.004$). Younger and more active patients did better in both groups. There were two failures in the autologous chondrocyte implantation group and one in the microfracture group. No serious complications were reported. Biopsy specimens were obtained from 84% of the patients, and histological evaluation of repair tissues showed no significant differences between the two groups. We did not find any association between the histological quality of the tissue and the clinical outcome according to the scores on the Lysholm or SF-36 form or the visual analog scale.

Conclusions: Both methods had acceptable short-term clinical results. There was no significant difference in macroscopic or histological results between the two treatment groups and no association between the histological findings and the clinical outcome at the two-year time-point.

Level of Evidence: Therapeutic study, Level I-1a (randomized controlled trial [significant difference]). See Instructions to Authors for a complete description of levels of evidence.

Articular cartilage injuries have a limited potential to heal, which over time may lead to osteoarthritis^{1,2}. Cartilage defects in the knee may cause pain, swelling, and catching. There are several different surgical procedures available to treat cartilage injuries, but no method has been judged superior. The ultimate aim of treatment is restoration

of normal knee function by regenerating hyaline cartilage in the defect and complete integration of the regenerated cartilage with the surrounding cartilage and underlying bone. Arthroscopic débridement and lavage may provide symptomatic relief for a limited time^{3,4}, although a controlled trial of débridement in patients with osteoarthritis of the knee showed the outcomes to be no better than those of treatment with a placebo⁵. However, it is important to distinguish between local cartilage defects and osteoarthritis.

Several marrow-stimulating procedures directed at the



A commentary is available with the electronic versions of this article, on our web site (www.jbjs.org) and on our quarterly CD-ROM (call our subscription department, at 781-449-9780, to order the CD-ROM).

recruitment of bone-marrow cells have been widely used to treat local cartilage defects. With these methods, the subchondral bone is penetrated to allow fibrin clot formation within the defect and then the creation of a repair tissue. Drilling, as described by Pridie⁶, has been used for decades. More recently, marrow-stimulating procedures such as abrasion⁷ and microfracture⁸⁻¹³ have been advocated. Other approaches to the treatment of full-thickness cartilage defects include methods of resurfacing with periosteum^{14,15}, perichondrium¹⁶, osteochondral plugs (mosaicplasty)¹⁷⁻²⁰, and allografts^{21,22}. Autologous chondrocyte implantation was first described in 1994²³. Encouraging primary results were reported, and further research was promoted. The technique has been widely used in many centers in the United States and Europe²³⁻³⁶. In a study in Sweden, use of the procedure on the femoral condyles led to a good or excellent long-term result in 89% of patients, and eight of twelve biopsy specimens showed findings consistent with hyaline tissue³⁴. Some authors have been skeptical, however, pointing out that the results of autologous chondrocyte implantation have not been proven to be better than those of other methods^{2,37,38}. Horas et al. found that, after two years of follow-up, the improvement provided by autologous chondrocyte implantation lagged behind that provided by osteochondral cylinder transplantation³⁷. In contrast, Bentley et al. recently found, in a randomized study, that the short-term clinical results were better after autologous chondrocyte implantation than they were after mosaicplasty²⁴. Both mosaicplasty and autologous chondrocyte implantation are relatively major surgical procedures, and the cartilage cell expansion necessary for autologous chondrocyte implantation is a demanding and expensive additional step. Microfracture, on the other hand, is a simple one-stage arthroscopic technique that has had better results than the Pridie drilling technique, with improvement achieved in up to 75% of patients after five years

of follow-up^{8-13,39}. However, the repair tissue seen after this procedure has been reported to be fibrocartilage or, at best, a hybrid of fibrocartilage and hyaline cartilage^{8-13,39}. Mosaicplasty techniques can be used only for smaller lesions because of the limited availability of donor plugs, whereas microfracture and autologous chondrocyte implantation are suitable for defects of up to at least 10 cm². We are not aware of any previous randomized controlled studies comparing these two methods. The objective of the present trial was to compare autologous chondrocyte implantation with microfracture in a randomized trial.

Materials and Methods

Eighty patients with a single symptomatic cartilage defect in a stable knee were enrolled in the study between January 1999 and February 2000. Experienced senior knee surgeons at each center selected the patients according to the inclusion and exclusion criteria in Table I. It was required that the symptoms (pain, catching, locking, or swelling with reduction in activities) were most likely related to the cartilage defect. All of the patients had a localized defect on the femoral condyle, and none had generalized osteoarthritis.

Forty patients were treated with autologous chondrocyte implantation and forty, with microfracture. Four university hospitals in Norway participated, with ten autologous chondrocyte implantation procedures and ten microfracture operations performed at each center by surgeons who were well trained in both techniques. Informed consent was obtained from all patients, and the study protocol was approved by the National Review Board. Financial support was granted by the Norwegian Ministry of Health. The International Cartilage Repair Society (ICRS) form⁴⁰ was used to collect demographic data and to record the history, symptoms, functional score, pain as indicated on a visual analog scale, characteristics

TABLE I Inclusion and Exclusion Criteria

Inclusion Criteria	Exclusion Criteria
Age between 18 and 45 yr	Alcohol or drug abuse during the last three years
Informed consent signed by patient	Osteoarthritis, rheumatoid arthritis, gout, Bechterew syndrome, or chondrocalcinosis
Patient understands rehabilitation protocol and is willing to follow it	Malalignment with >5° valgus or varus compared with normal
Isolated Outerbridge grade-3 or 4 defect on medial or lateral femoral condyle or trochlea	Patellofemoral instability
Size of defect between 2 and 10 cm ² after débridement to healthy cartilage; osteochondral lesions up to 10 mm in depth	Overweight (body mass index >30)
Knee not too tight and does not have fixed flexion deformity	Serious illness
Knee is stable	
Only symptomatic lesions are included	
Normal standing radiographs performed	

of the cartilage defect, and findings of the baseline clinical examination. In addition, the Lysholm score⁴¹, the Tegner score⁴², and the Short Form-36 (SF-36)⁴³ were used. Weight-bearing standing radiographs of the knees were made for all patients. Patients were excluded if there was narrowing of the joint space or there were other radiographic signs of osteoarthritis. Patients who had multiple lesions in the knee or arthroscopically verified general osteoarthritis were excluded as well. Some patients were excluded because these findings were observed during arthroscopy.

With use of sealed envelopes, patients who fulfilled the inclusion criteria were randomized during the arthroscopy to be treated with either autologous chondrocyte implantation or microfracture. The microfracture procedures were done during the arthroscopy, whereas the patients randomized to be treated with autologous chondrocyte implantation had cartilage samples harvested, for cell extraction, during the arthroscopy; those patients then returned for cell implantation through an arthrotomy after approximately four weeks. Patients in both groups were hospitalized for four days after their final operative procedure and then were treated with an identical rehabilitation protocol. Continuous passive motion and partial weight-bearing with crutches were started on the first postoperative day after both procedures. The patients then remained partially weight-bearing (20 kg) with crutches for eight weeks. Full weight-bearing was introduced between eight and twelve weeks postoperatively, depending on the patient's clinical status and function. Stationary bicycling was started as soon as possible.

An independent observer performed a follow-up clinical examination at twelve and twenty-four months using the same evaluation forms as had been used preoperatively. Two years after the cartilage repair, second-look arthroscopy with biopsy for histological evaluation was carried out. The ICRS cartilage repair assessment for macroscopic evaluation during arthroscopy was used. The operation was considered to have failed if the patient needed a reoperation because of symptoms due to a lack of healing of the primary treated defect. The need for shaving or trimming a lesion was not defined as a failure.

Trauma was the most common etiology of the defects (65% of the cases), followed by osteochondritis dissecans (28%). Most (89%) of the defects were located on the medial femoral condyle, with the remaining located on the lateral femoral condyle. None of the patients had a defect in the trochlea. All of the patients had had chronic knee problems, with a median duration of symptoms of thirty-six months, and 94% had had previous knee surgery before inclusion in the study. These operations included anterior cruciate ligament reconstruction (fifteen patients), meniscal surgery (fourteen), arthroscopic lavage and débridements (twenty-nine), Pridie drilling (three), and operations for osteochondritis dissecans such as drilling or fixation of a fragment (thirteen). The patients treated with autologous chondrocyte implantation had undergone an average of 1.6 previous surgical procedures to treat the cartilage defect, and those in the microfracture group had undergone an average of 1.4. Preoperatively, no significant differences were found be-

tween the autologous chondrocyte implantation and the microfracture group with regard to age (mean, 33.3 and 31.1 years, respectively), sex (60% male), defect size (mean, 5.1 and 4.5 cm², respectively), body weight, or baseline clinical data. Most of the patients had an Outerbridge⁴⁴ grade-3 or 4 defect; only three patients had a grade-2 defect.

Statistical Methods

A sample-size estimation showed that forty patients in each group would be required to demonstrate a difference between the Lysholm and SF-36 scores of the two groups of at least 0.75 standard deviation from the mean, with an alpha level of 0.05 and a beta level of 90%.

The data were analyzed with the SPSS statistical package (SPSS, Chicago, Illinois). T tests, the Pearson chi-square and Mann-Whitney U tests, analysis of covariance, and multiple analysis of variance were used. The level of significance was $p < 0.05$.

Autologous Chondrocyte Implantation

The surgical technique described by Brittberg et al.²³ was used. Cartilage was harvested arthroscopically from a low-load-bearing area on the proximal part of the medial femoral condyle of the affected knee. The biopsy specimen was then placed in a sterile transport medium provided by Genzyme (Boston, Massachusetts) and was sent by express air transport for commercial cell culturing in their laboratory in Boston. Approximately four weeks later, the cells were returned for implantation. An arthrotomy was performed, and the defect was débrided to healthy surrounding cartilage. Periosteum was taken from the proximal part of the tibia or distal part of the femur and was sutured to the rim of the débrided defect; fibrin glue was used to form a watertight chamber. The cultured chondrocytes were then injected beneath the patch, and a final suture and fibrin sealant were placed at the injection site.

Microfracture

The technique introduced by Steadman et al.¹² twenty years ago was used. The procedure consists of accurate débridement of all unstable and damaged cartilage in the lesion, including the calcified layer down to the subchondral bone plate. All loose or marginally attached cartilage was also débrided from the surrounding rim of the defect, to form a stable perpendicular edge of healthy cartilage. An arthroscopic awl was then used to make multiple holes in the defect, 3 to 4 mm apart. In order to preserve the subchondral bone plate, care was taken not to make the holes so close to each other that they could break into one another.

Histological Analysis

Two-millimeter-diameter core-biopsy specimens were obtained during the follow-up arthroscopy. The specimens were taken from the central part of the treated defects and included both repair cartilage tissue and subchondral bone. The specimens were fixed in 4% formaldehyde and sent to the pathologist at the University Hospital in Tromsø, where they were

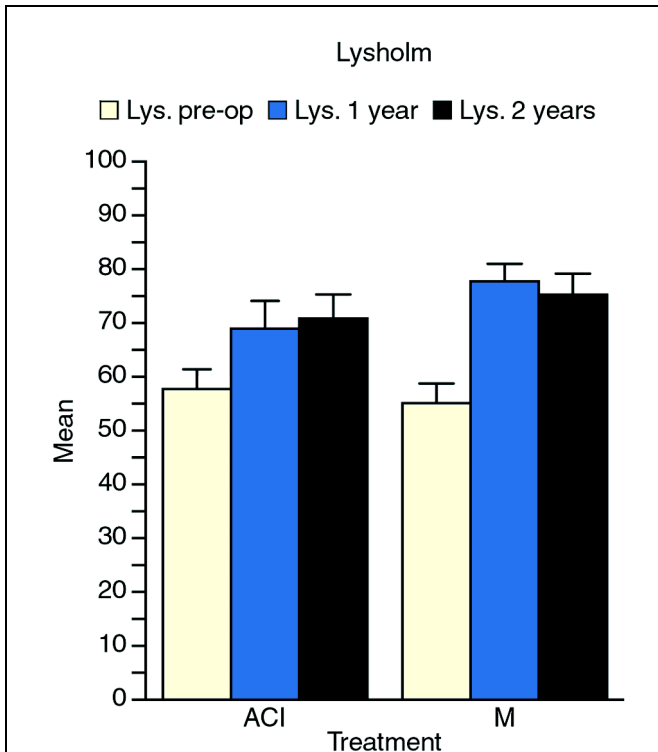


Fig. 1
Histogram showing the mean Lysholm scores preoperatively and at one and two years after the surgical procedure. The Lysholm score at two years was significantly improved compared with the baseline value in both groups ($p = 0.003$ for the autologous chondrocyte implantation [ACI] group and $p < 0.0001$ for the microfracture [M] group). No significant differences between the groups were detected ($p = 0.092$).

embedded in paraffin, sectioned at a 5- μm thickness, and then stained with hematoxylin and eosin. The histological evaluation was performed by a pathologist in Tromsø (V.I.) and a clinical scientist (S.R.) who specializes in histological analysis of cartilage. Both were blinded to the type of treatment that the patient had received. Concentrating particularly on the lower region of the biopsy specimen, they arbitrarily ranked the repair cartilage as hyaline (Group 1), fibrocartilage-hyaline mixture (Group 2), or fibrocartilage (Group 3), or they recorded that there was no repair tissue (Group 4).

Hyaline cartilage was clearly differentiated from fibrocartilage by the homogeneous appearance of the matrix, particularly when viewed under polarized light, and the round or oval shape of the cells, which often were surrounded by lacunae. Fibrocartilage, in contrast, had obvious bundles of collagen fibers, lying in a random, irregular manner, when viewed under polarized light. Samples in which $\geq 60\%$ of the area of matrix was hyaline cartilage were categorized as Group 1; those in which $>40\%$ but $<60\%$ was hyaline cartilage, as Group 2; and those in which $\geq 60\%$ was fibrocartilage, as Group 3. Samples were categorized as Group 4 when they

were inadequate or when no obvious repair tissue was present and the tissue was predominantly bone. Group-4 specimens may have been that way in vivo or the findings may have been due to sample handling. Examples of the histological appearance and the ranking of the repair tissue are shown in Figure 5. The categorizations were the result of the final consensus between the two assessors.

Results

At two years, the Lysholm score had improved significantly, compared with the baseline score, in both the autologous chondrocyte implantation group ($p < 0.003$) and the microfracture group ($p < 0.0001$) (Fig. 1). Pain, according to the visual analog scale, was significantly reduced in both groups ($p < 0.0001$ for both) (Fig. 2), with 78% of the patients treated with autologous chondrocyte implantation and 75% of those treated with microfracture having less pain at the two-year follow-up evaluation than they had had at the baseline evaluation. The two groups did not differ significantly with regard to the improvements in the Lysholm and pain scores at one and two

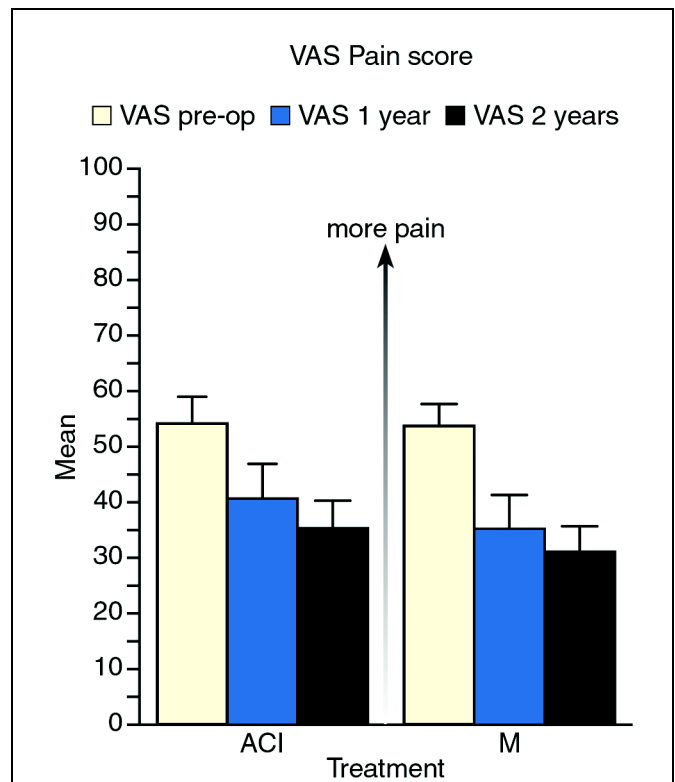
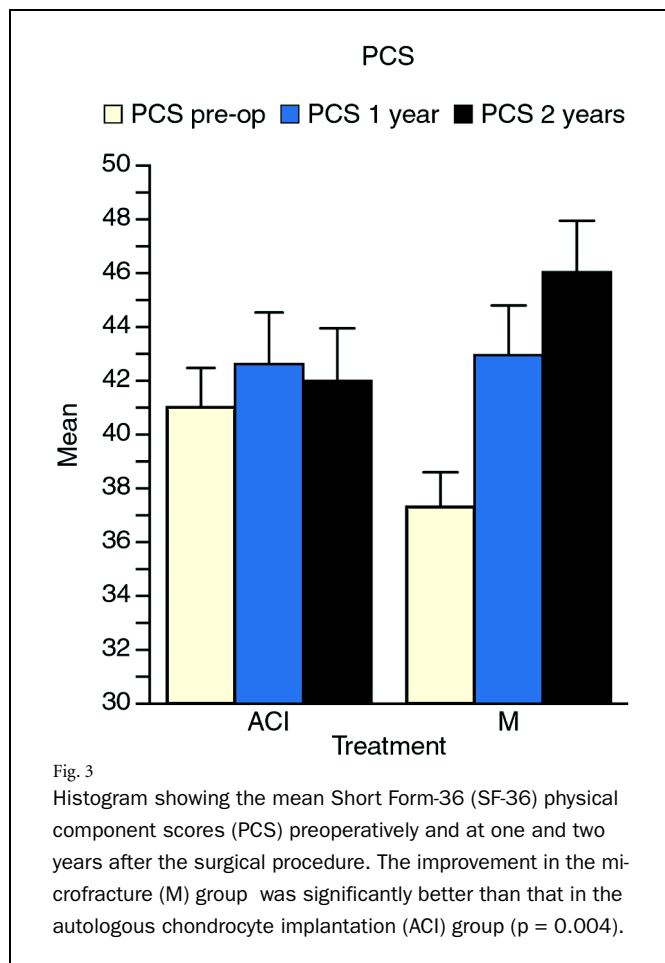


Fig. 2
Histogram showing the mean pain scores, according to a visual analog scale (VAS), preoperatively and at one and two years after the surgical procedure. The pain score at two years was significantly improved compared with the baseline value in both the autologous chondrocyte implantation (ACI) group and the microfracture (M) group ($p < 0.0001$ for both). No significant differences between the two groups were detected ($p = 0.292$).



years. However, the microfracture group had significantly more improvement in the SF-36 physical component score in the first two years than did the autologous chondrocyte implantation group ($p = 0.004$). As seen in Figure 3, there was an almost significant difference in the preoperative physical component scores between the groups ($p = 0.0506$). We performed an analysis of covariance with the preoperative physical component score as a covariate and found a high correlation between the preoperative and postoperative physical component scores ($p = 0.000001$). With the preoperative physical component scores taken into account, the microfracture group still had a significantly better result than did the autologous chondrocyte implantation group ($p = 0.01$). No difference in the SF-36 mental health subscale score was detected between the groups.

Regardless of their treatment group, younger patients (less than thirty years old) had a better clinical outcome than did older patients ($p = 0.007$). Also, in both groups, more active patients, as indicated by a Tegner score of >4 points, had a significantly better clinical result (according to the Lysholm score, visual analog scale, and SF-36 physical component score) than did less active patients ($p = 0.0005$).

In the microfracture group, patients with a lesion smaller than 4 cm^2 had significantly better clinical results (according

to the Lysholm score, visual analog scale, and SF-36 physical component score) than did those with a bigger defect ($p < 0.003$). We did not find this association between the size of the defect and the clinical outcome in the autologous chondrocyte implantation group ($p > 0.89$). We also did not find any significant differences in clinical results between the patients who had and had not had previous surgery involving the anterior cruciate ligament ($p > 0.4$) or meniscus ($p > 0.28$), but the numbers of patients were small for statistical analysis.

The ICRS macroscopic evaluations during the second-look arthroscopy did not show any difference between the autologous chondrocyte implantation and microfracture groups (Fig. 4). The findings were graded as nearly normal in both groups. Biopsies were performed in sixty-seven patients: thirty-two treated with autologous chondrocyte implantation and thirty-five treated with microfracture. Six patients declined to have the biopsy, three patients could not return for the second-look arthroscopy and biopsy because of pregnancy at the time of the two-year evaluation, and the surgeons did not perform suitable biopsies in four patients. The results of the histological evaluations are shown in Figures 5 and 6. Thirty-nine percent of the biopsy specimens had at least some hyaline cartilage present, although few were composed totally of hyaline cartilage. In contrast, 43% had fibrocartilage throughout most of their depth (Group 3). There was no significant difference between the groups with regard to the frequency with which hyaline and fibrocartilage repair tissue were found ($p = 0.08$). With the same power, we would have needed 120 biopsies to find a significant difference between the two groups. Also, there was no association between clinical outcome (according to the Lysholm score, visual analog scale, and SF-36 physical component score) and the histological quality (according to the semiquantitative grading of the specimens as group 1, 2, 3, or 4) ($p > 0.3$, two-sided t test).

There were two failures, at six and eighteen months, in the autologous chondrocyte implantation group, and one failure, at fifteen months, in the microfracture group. The patients who had a failure were all symptomatic and underwent revision with another cartilage treatment; they were then excluded from the study.

Arthroscopic débridement was performed prior to the second-look arthroscopy in ten patients (25%) in the autologous chondrocyte implantation group and in four (10%) in the microfracture group. In the autologous chondrocyte implantation group, shaving was done mainly because of symptomatic tissue hypertrophy. In the microfracture group, one patient had arthrofibrosis, requiring manipulation and operative release, and the other three had minor débridements. No serious complications, such as deep infection or a thromboembolic event, were recorded. One of the patients treated with autologous chondrocyte implantation was diagnosed as having psoriatic arthritis in the operatively treated knee one year after the surgery. As was the case prior to the surgery, there was no evidence of osteoarthritis on standing radiographs at the two-year follow-up evaluation.

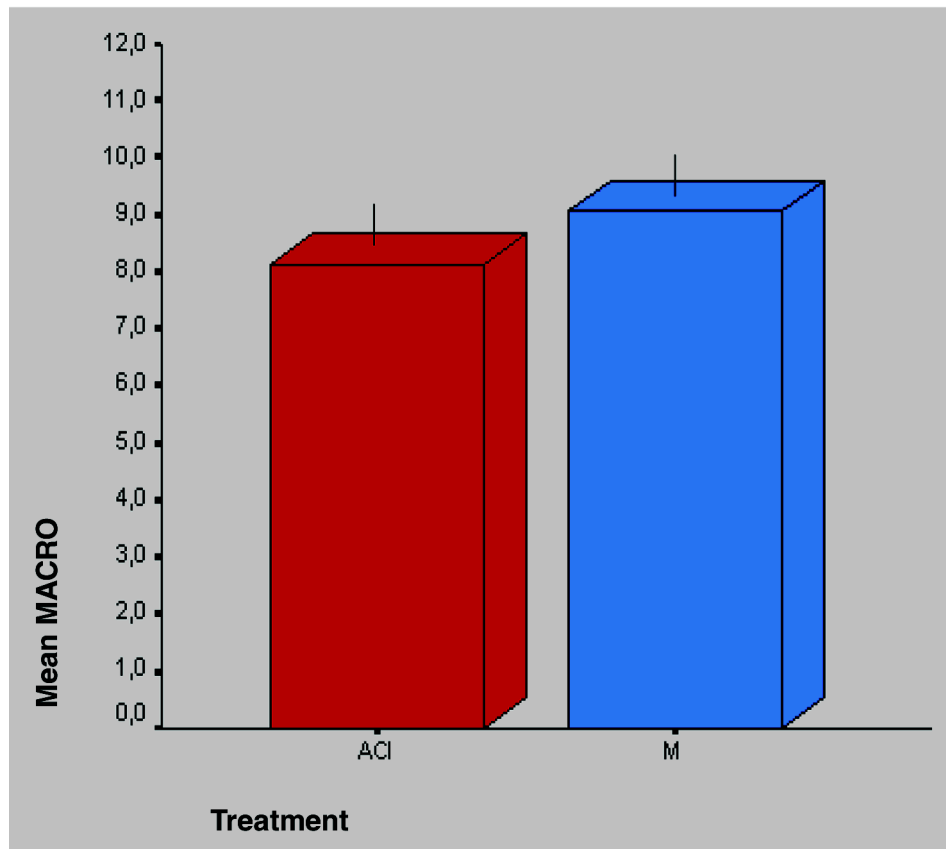
Discussion

There have been several uncontrolled studies on both autologous chondrocyte implantation and microfracture in which good and excellent results were reported^{8-13,23,25-31,33-36,39,45}. The present study is, to our knowledge, the first to compare autologous chondrocyte implantation and microfracture in a randomized trial with independent observers judging the clinical outcome and quality of the repair tissue. Autologous chondrocyte implantation and osteochondral plugs were compared in a prospective comparative trial by Horas et al., who did not find the results of autologous chondrocyte implantation to be as good as had been previously reported in the literature³⁷. In their study, the clinical results of autologous chondrocyte implantation were inferior to those provided by osteochondral plugs, and defects treated with autologous chondrocyte implantation were primarily filled with fibrocar-

tilage. In contrast, Bentley et al. reported that autologous chondrocyte implantation yielded better results than did osteochondral plugs (mosaicplasty), and they found hyaline cartilage in seven of nineteen biopsy specimens obtained one year after autologous chondrocyte implantation²⁴.

In our trial, we found that autologous chondrocyte implantation and microfracture yielded similar clinical results. Lysholm scores and pain scores improved significantly after both operations, with approximately 76% of all patients having less pain at the two-year follow-up examination than they had had preoperatively. There was no significant difference between the groups with regard to these scores at either one or two years. However, the improvement in the SF-36 physical component score was significantly better in the microfracture group than it was in the autologous chondrocyte implantation group. One reason for this could be that microfracture involves

Macroscopic evaluation



p= 0.170

Fig. 4

Histogram showing the mean scores on the ICRS macroscopic evaluation (MACRO) at the second-look arthroscopy performed at two years postoperatively. The maximum score for the evaluation is 12 points. No significant difference between the autologous chondrocyte implantation (ACI) and microfracture (M) groups was detected.

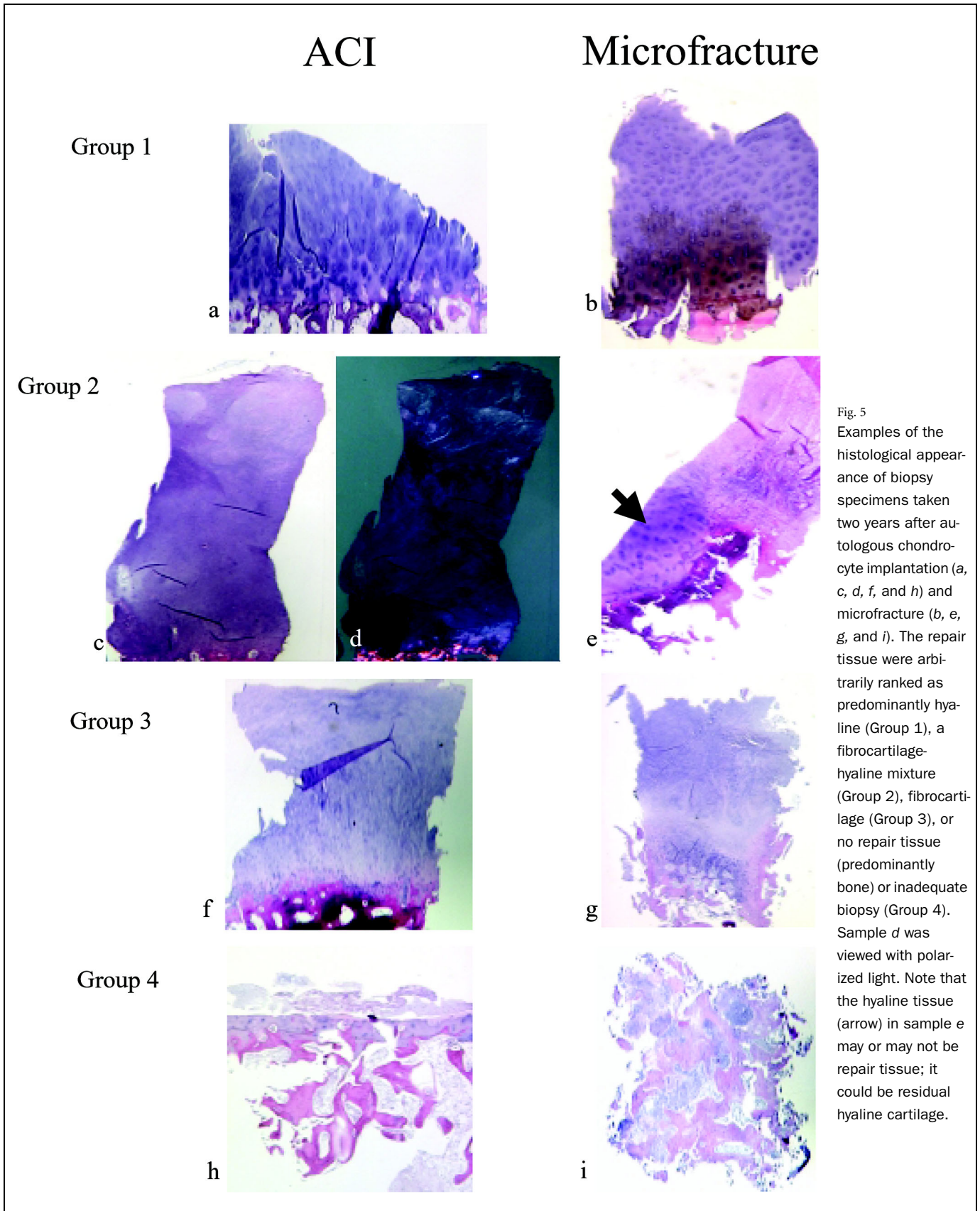


Fig. 5 Examples of the histological appearance of biopsy specimens taken two years after autologous chondrocyte implantation (a, c, d, f, and h) and microfracture (b, e, g, and i). The repair tissue were arbitrarily ranked as predominantly hyaline (Group 1), a fibrocartilage-hyaline mixture (Group 2), fibrocartilage (Group 3), or no repair tissue (predominantly bone) or inadequate biopsy (Group 4). Sample d was viewed with polarized light. Note that the hyaline tissue (arrow) in sample e may or may not be repair tissue; it could be residual hyaline cartilage.

Histology

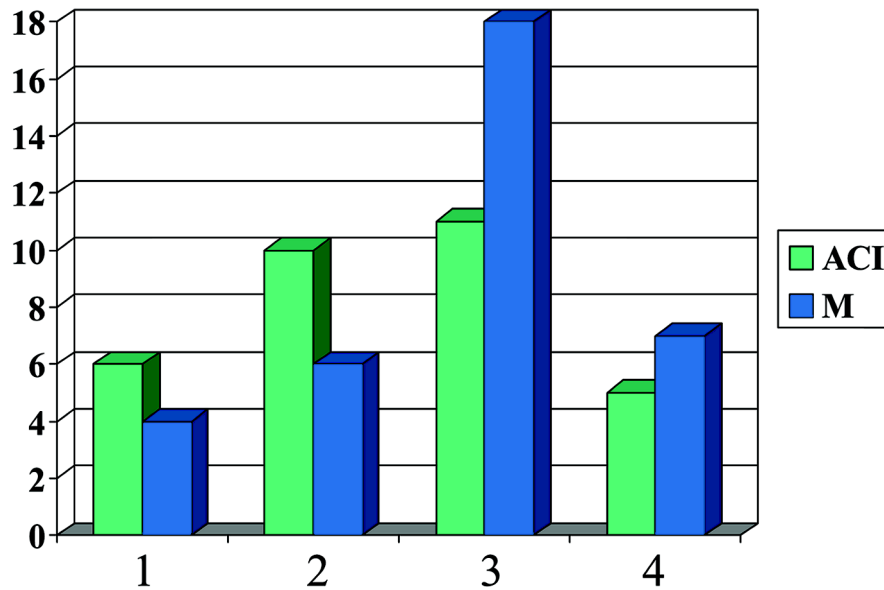


Fig. 6

Histogram showing the results of the histological evaluation of biopsy specimens taken during second-look arthroscopy from the central part of the treated defects in the autologous chondrocyte implantation (ACI) group and the microfracture (M) group. Group-1 tissue is predominantly hyaline; Group-2, a fibrocartilage-hyaline mixture; and Group-3, fibrocartilage. Group 4 indicates an inadequate biopsy or no repair tissue (predominantly bone).

less surgery and therefore the rehabilitation is easier than that following autologous chondrocyte implantation. However, one could expect a smaller difference between groups after two years compared with the difference at one year. It is important to note that our cohort of patients had chronic lesions (median duration of symptoms, thirty-six months), with a mean of 1.5 previous operations. This may explain why their final clinical scores were not higher (e.g., the Lysholm scores were in the 70 to 75-point range).

The arthroscopic evaluation at two years also demonstrated similar results in the two groups. The macroscopic classifications of the repair tissue did not differ significantly, with the mean values classified as nearly normal in both groups, indicating acceptable repair and filling of the treated defects.

We also did not find any significant differences regarding histological quality between the two treatment groups. These results are not consistent with those in the first study by Brittberg et al., in which eleven of fifteen patients had "hyaline-like cartilage" after autologous chondrocyte implantation²³. However, 50% of the biopsies in the autologous chondrocyte implantation group in our study showed some hyaline tissue (Groups 1 and 2). There was a tendency in our study for the autologous chondrocyte implantation procedure to result in more hyaline repair cartilage than the microfracture procedure, but this was not a significant finding with the numbers available.

Peterson et al. reported a failure rate of 11% after autologous chondrocyte implantation of the femoral condyles, with most of the failures occurring less than two years post-operatively³⁴. They concluded that a graft surviving for two years is likely to remain viable three to eight years later and that autologous chondrocyte implantation results in a durable repair in the majority of patients. Roberts et al. found that biopsies showing hyaline morphology had been performed at a longer time interval after autologous chondrocyte implantation (average, 19.8 months) than had biopsies showing fibrocartilage (average, 12.0 months)⁴⁵. This observation suggests that continuous remodeling of the graft may take place and that the transplant may become more hyaline with time.

It has been suggested that traditional drilling and débridement lead to good and excellent results for up to five years and that the results then decline². Histological analysis of repair tissue after such operations was reported to show mainly fibrocartilage². However, Steadman et al. suggested that microfracture can provide a more durable repair than can traditional drilling and that the repair tissue may be a hybrid of hyaline cartilage and fibrocartilage³⁹. That observation is in agreement with our findings.

In our study, younger and more active patients in both treatment groups had a better clinical outcome. This finding is

consistent with those of previous studies of both animals and humans^{8,15}.

The two-year failure rates in our study were low (5% and 2.5%) and were comparable with those in previously published reports^{24,30,34,37,39}. Ten reoperations were performed in the autologous chondrocyte implantation group and four, in the microfracture group. Most of these were minor débridements, but it is remarkable that one of every four patients treated with autologous chondrocyte implantation needed this procedure before the planned two-year second-look arthroscopy. Hypertrophy of tissue (probably periosteum) was the major reason for these reoperations. Using a collagen membrane instead of periosteum possibly could reduce this problem. Peterson⁴⁶ expressed the opinion that a periosteal flap that is too thick (not cleaned properly of fat and fibrous tissue) may be one reason for hypertrophy. In addition, autologous chondrocyte implantation is complex surgery, and there is thus a learning curve for the surgeons. All surgeons participating in this study were trained in both procedures, but autologous chondrocyte implantation is a more technically demanding procedure than microfracture; it also requires two separate surgical procedures. Because microfracture is a relatively simple one-stage procedure, it may be more suitable for a primary first-line cartilage repair of a local contained defect³⁹. In patients in whom microfracture has failed and in those with bigger, noncontained defects, autologous chondrocyte implantation may be a better option.

Randomized controlled trials of surgical procedures are difficult to perform. Double blinding is difficult, particularly in this study, in which it was not possible to blind either the patients or the surgeons to which treatment was being given because of the two-stage nature of the autologous chondrocyte implantation.

This is one of the largest, most comprehensive studies of biopsy specimens from cartilage repair sites in patients treated with autologous chondrocyte implantation available to date, and it should add considerably to the database of histological results after cartilage resurfacing techniques.

In conclusion, both methods appear to have acceptable short-term results. Younger and more active patients have better clinical results regardless of which type of treatment they

receive. According to the SF-36 physical component scores at two years postoperatively, the improvement in the microfracture group was significantly better than that in the autologous chondrocyte implantation group, but it remains to be seen if that difference is maintained into the future. No significant differences were found regarding the macroscopic appearance or the histological quality of the repair tissue, and we did not find any association between the histological quality of the tissue and the clinical outcome. Mid-term and long-term follow-up is needed to determine if one method is better than the other for generating long-lasting hyaline cartilage and alleviating symptoms. ■

NOTE: The authors thank Tom Wilsgaard and Jan Herman Kuiper for their statistical assistance.

Gunnar Knutsen, MD
Vidar Isaksen, MD
Oddmund Johansen, MD, PhD
Department of Orthopaedic Surgery, University Hospital Tromsø, 9038 Tromsø, Norway. E-mail address for G. Knutsen: gunnar.knutsen@unn.no

Lars Engebretsen, MD, PhD
Tom C. Ludvigsen, MD
Oslo Orthopaedic University Clinic, 0407 Oslo, Norway

Jon Olav Drogset, MD
Torbjørn Grøntvedt, MD, PhD
University Hospital Trondheim, 7006 Trondheim, Norway

Eirik Solheim, MD, PhD
Torbjørn Strand, MD
Deaconess University Hospital Bergen, 5009 Bergen, Norway

Sally Roberts, PhD
Robert Jones and Agnes Hunt Orthopaedic Hospital, Oswestry, Shropshire SY10 7AG, United Kingdom

In support of their research or preparation of this manuscript, one or more of the authors received grants or outside funding from the Norwegian Ministry of Health. None of the authors received payments or other benefits or a commitment or agreement to provide such benefits from a commercial entity. No commercial entity paid or directed, or agreed to pay or direct, any benefits to any research fund, foundation, educational institution, or other charitable or nonprofit organization with which the authors are affiliated or associated.

References

- Buckwalter JA, Mankin HJ.** Articular cartilage. Part II: degeneration and osteoarthritis, repair, regeneration, and transplantation. *J Bone Joint Surg Am.* 1997;79:612-32.
- Hunziker EB.** Articular cartilage repair: basic science and clinical progress. A review of the current status and prospects. *Osteoarthritis Cartilage.* 2002; 10:432-63.
- Hubbard MJ.** Articular debridement versus washout for degeneration of the medial femoral condyle. A five-year study. *J Bone Joint Surg Br.* 1996; 78:217-9.
- Jackson RW.** Meniscal and articular cartilage injury in sport. *J R Coll Surg Edinb.* 1989;34(6 Suppl):S15-7.
- Moseley JB, O'Malley K, Petersen NJ, Menke TJ, Brody BA, Kuykendall DH, Hollingsworth JC, Ashton CM, Wray NP.** A controlled trial of arthroscopic surgery for osteoarthritis of the knee. *N Engl J Med.* 2002;347:81-8.
- Pridie KH.** A method of resurfacing osteoarthritic knee joints. *J Bone Joint Surg Br.* 1959;41:618-9.
- Johnson LL.** Arthroscopic abrasion arthroplasty historical and pathologic perspective: present status. *Arthroscopy.* 1986;2:54-69.
- Blevins FT, Steadman JR, Rodrigo JJ, Silliman J.** Treatment of articular cartilage defects in athletes: an analysis of functional outcome and lesion appearance. *Orthopedics.* 1998;21:761-8.
- Passler HH.** [Microfracture for treatment of cartilage defects]. *Zentralbl Chir.* 2000;125:500-4. German.
- Sledge SL.** Microfracture techniques in the treatment of osteochondral injuries. *Clin Sports Med.* 2001;20:365-77.
- Steadman JR, Rodkey WG, Rodrigo JJ.** Microfracture: surgical technique and rehabilitation to treat chondral defects. *Clin Orthop.* 2001;391(Suppl):S362-9.
- Steadman JR, Rodkey WG, Briggs KK.** Microfracture to treat full-thickness chondral defects: surgical technique, rehabilitation, and outcomes. *J Knee Surg.* 2002;15:170-6.
- Steadman JR, Rodkey WG, Briggs KK, Rodrigo JJ.** [The microfracture tech-

- nique in the management of complete cartilage defects in the knee joint]. *Orthopade*. 1999;28:26-32. German.
14. **Lorentzon R, Alfredson H, Hildingsson C.** Treatment of deep cartilage defects of the patella with periosteal transplantation. *Knee Surg Sports Traumatol Arthrosc*. 1998;6:202-8.
 15. **O'Driscoll SW, Fitzsimmons JS.** The role of periosteum in cartilage repair. *Clin Orthop*. 2001;391(Suppl):S190-207.
 16. **Homminga GN, Bulstra SK, Bouwmeester PS, van der Linden AJ.** Perichondral grafting for cartilage lesions of the knee. *J Bone Joint Surg Br*. 1990;72:1003-7.
 17. **Bobic V.** Arthroscopic osteochondral autograft transplantation in anterior cruciate ligament reconstruction: a preliminary clinical study. *Knee Surg Sports Traumatol Arthrosc*. 1996;3:262-4.
 18. **Hangody L, Feczko P, Bartha L, Bodo G, Kish G.** Mosaicplasty for the treatment of articular defects of the knee and ankle. *Clin Orthop*. 2001;391(Suppl):S328-36.
 19. **Jakob RP, Franz T, Gautier E, Mainil-Varlet P.** Autologous osteochondral grafting in the knee: indication, results, and reflections. *Clin Orthop*. 2002;401:170-84.
 20. **Solheim E.** [Mosaicplasty in articular cartilage injuries of the knee]. *Tidsskr Nor Laegeforen*. 1999;119:4022-5. Norwegian.
 21. **Aubin PP, Cheah HK, Davis AM, Gross AE.** Long-term followup of fresh femoral osteochondral allografts for posttraumatic knee defects. *Clin Orthop*. 2001;391(Suppl):S318-27.
 22. **Gross AE.** Repair of cartilage defects in the knee. *J Knee Surg*. 2002;15:167-9.
 23. **Brittberg M, Lindahl A, Nilsson A, Ohlsson C, Isaksson O, Peterson L.** Treatment of deep cartilage defects in the knee with autologous chondrocyte transplantation. *N Engl J Med*. 1994;331:889-95.
 24. **Bentley G, Biant LC, Carrington RW, Akmal M, Goldberg A, Williams AM, Skinner JA, Pringle J.** A prospective, randomised comparison of autologous chondrocyte implantation versus mosaicplasty for osteochondral defects in the knee. *J Bone Joint Surg Br*. 2003;85:223-30.
 25. **Brittberg M.** Autologous chondrocyte transplantation. *Clin Orthop*. 1999;367(Suppl):S147-55.
 26. **Brittberg M, Tallheden T, Sjogren-Jansson B, Lindahl A, Peterson L.** Autologous chondrocytes used for articular cartilage repair: an update. *Clin Orthop*. 2001;391(Suppl):S337-48.
 27. **Gillogly SD, Voight M, Blackburn T.** Treatment of articular cartilage defects of the knee with autologous chondrocyte implantation. *J Orthop Sports Phys Ther*. 1998;28:241-51.
 28. **Knutsen G, Solheim E, Johansen O.** [Treatment of focal cartilage injuries in the knee]. *Tidsskr Nor Laegeforen*. 1998;118:2493-7. Norwegian.
 29. **Marcacci M, Zaffagnini S, Kon E, Visani A, Iacono F, Loreti I.** Arthroscopic autologous chondrocyte transplantation: technical note. *Knee Surg Sports Traumatol Arthrosc*. 2002;10:154-9.
 30. **Micheli LJ, Browne JE, Erggelet C, Fu F, Mandelbaum B, Moseley JB, Zurawski D.** Autologous chondrocyte implantation of the knee: multicenter experience and minimum 3-year follow-up. *Clin J Sport Med*. 2001;11:223-8.
 31. **Minas T, Peterson L.** Advanced techniques in autologous chondrocyte transplantation. *Clin Sports Med*. 1999;18:13-44, v-vi.
 32. **Muellner T, Knopp A, Ludvigsen TC, Engebretsen L.** Failed autologous chondrocyte implantation. Complete atraumatic graft delamination after two years. *Am J Sports Med*. 2001;29:516-9.
 33. **Peterson L, Minas T, Brittberg M, Nilsson A, Sjogren-Jansson E, Lindahl A.** Two- to 9-year outcome after autologous chondrocyte transplantation of the knee. *Clin Orthop*. 2000;374:212-34.
 34. **Peterson L, Brittberg M, Kiviranta I, Akerlund EL, Lindahl A.** Autologous chondrocyte transplantation. Biomechanics and long-term durability. *Am J Sports Med*. 2002;30:2-12.
 35. **Richardson JB, Caterson B, Evans EH, Ashton BA, Roberts S.** Repair of human articular cartilage after implantation of autologous chondrocytes. *J Bone Joint Surg Br*. 1999;81:1064-8.
 36. **Drobnic M, Kregar-Velikonja N, Radosavljevic D, Gorenssek M, Koritnik B, Malicev E, Wozniak G, Jeras M, Knezevic M.** The outcome of autologous chondrocyte transplantation treatment of cartilage lesions in the knee. *Cell Mol Biol Lett*. 2002;7:361-3.
 37. **Horas U, Pelinkovic D, Herr G, Aigner T, Schnettler R.** Autologous chondrocyte implantation and osteochondral cylinder transplantation in cartilage repair of the knee joint. A prospective, comparative trial. *J Bone Joint Surg Am*. 2003;85:185-92.
 38. **Messner K, Gillquist J.** Cartilage repair. A critical review. *Acta Orthop Scand*. 1996;67:523-9.
 39. **Steadman RJ, Rodkey WG, Singleton SB, Briggs KK.** Microfracture technique for full thickness chondral defects: technique and clinical results. *Oper Tech Orthop*. 1997;7:300-5.
 40. **Brittberg M, Winalski CS.** Evaluation of cartilage injuries and repair. *J Bone Joint Surg Am*. 2003;85(Suppl 2):58-69.
 41. **Lysholm J, Gillquist J.** Evaluation of knee ligament surgery results with special emphasis on use of a scoring scale. *Am J Sports Med*. 1982;10:150-4.
 42. **Tegner Y, Lysholm J.** Rating systems in the evaluation of knee ligament injuries. *Clin Orthop*. 1985;198:43-9.
 43. **Ware JE Jr, Sherbourne CD.** The MOS 36-item short-form health survey (SF-36). I. Conceptual framework and item selection. *Med Care*. 1992;30:473-83.
 44. **Outerbridge RE.** The etiology of chondromalacia patellae. *J Bone Joint Surg Br*. 1961;43:752-7.
 45. **Roberts S, McCall IW, Darby AJ, Menage J, Evans EH, Harrison PE, Richardson JB.** Autologous chondrocyte implantation for cartilage repair: monitoring its success by magnetic resonance imaging and histology. *Arthritis Res Ther*. 2003;5:R60-73.
 46. **Peterson L.** Personal communication, April 4, 2003.