

# The Role of the Scapula in the Rehabilitation of Shoulder Injuries

Michael L. Voight, DPT, OCS, SCS, ATC; Brian C. Thomson, SPT

Belmont University, Nashville, TN

**Objective:** To present a clinical understanding of the role the scapula plays in the mechanics of shoulder function and specialized techniques for the rehabilitation of injuries around the shoulder girdle.

**Background:** The scapular musculature is often neglected in the evaluation and treatment of shoulder injuries. This lack of attention often degenerates into the incomplete evaluation and rehabilitation of scapular dysfunction. Dysfunction or weakness of the scapular stabilizers often results in altered biomechanics of the shoulder girdle. The altered biomechanics can result in (1) abnormal stresses to the anterior capsular structures, (2) the

increased possibility of rotator cuff compression, and (3) decreased performance.

**Description:** We review the anatomy and role of the scapula, the pathomechanics of injury and dysfunction, and the evaluation and rehabilitation of the scapula.

**Clinical Advantage:** Knowledge of how the scapular muscles influence function at the shoulder builds a strong foundation for the clinician to develop rehabilitation programs for the shoulder.

**Key Words:** scapular rehabilitation, shoulder rehabilitation, impingement syndrome, rotator cuff

The role of the scapula in upper extremity function has received considerable interest in recent years as our knowledge of the shoulder and surrounding structures has increased. The scapula plays several roles in facilitating optimal shoulder function when scapular anatomy and biomechanics interact to produce efficient movement. In normal upper-quarter function, the scapula provides a stable base from which glenohumeral mobility occurs.<sup>1</sup> Stability at the scapulothoracic joint depends on the surrounding musculature. The scapular muscles must dynamically position the glenoid so that efficient glenohumeral movement can occur. When weakness or dysfunction is present in the scapular musculature, normal scapular positioning and mechanics may become altered.<sup>1</sup> When the scapula fails to perform its stabilization role, shoulder function is inefficient, which can result not only in decreased neuromuscular performance but also may predispose the individual to shoulder injury.<sup>1</sup> We explore and review the role of the scapula in function and describe how to evaluate and rehabilitate scapular dysfunction.

## ANATOMY

The scapulothoracic joint is one of the least congruent joints in the body. No actual bony articulation exists between the scapula and the thorax, which allows tremendous mobility in many directions, including protraction, retraction, elevation, depression, and rotation. The lack of bony attachment predisposes this joint to pathologic movement, and, consequently, makes the glenohumeral joint highly dependent on the surrounding musculature for stability and normal motion.<sup>2-5</sup> The scapula is attached to the thorax by ligamentous

attachments at the acromioclavicular joint and through a suction mechanism provided by the muscular attachments of the serratus anterior and subscapularis.<sup>2</sup> This suction mechanism holds the scapula in close proximity to the thorax and allows it to glide during movements of the joint.<sup>2</sup>

While many muscles serve to stabilize the scapula, the main stabilizers are the levator scapulae, rhomboids major and minor, serratus anterior, and trapezii. The glenohumeral protectors include the muscles of the rotator cuff: the supraspinatus, infraspinatus, teres minor, and subscapularis.<sup>4-8</sup> These muscle groups function through synergistic cocontraction to anchor the scapula and guide movement. The scapula moves through a gliding mechanism in which the concave anterior surface of the scapula moves on the convex posterolateral surface of the thoracic cage.<sup>2</sup> These muscles work together to coordinate the balance of movement between the shoulder joints, thereby maintaining scapulohumeral rhythm.<sup>4,6,9</sup> When the muscles are weak or fatigued, scapulohumeral rhythm is compromised, and shoulder dysfunction results.<sup>4,8,10</sup> This dysfunction can cause microtrauma in the shoulder muscles, capsule, and ligamentous tissue and lead to impingement.<sup>3-6</sup>

During all movements of the glenohumeral joint (especially movements involving more than 90° of flexion or abduction), it is of paramount importance that the scapular-stabilizing musculature be strong enough to properly position the scapula. For example, the biomechanical research of both Jobe and Pink<sup>6</sup> and Bak and Faunt<sup>10</sup> demonstrated that if weakness or fatigue of any of the aforementioned structures occurs, scapulohumeral rhythm is disrupted, and secondary impingement (defined as a relative decrease in the subacromial space due to instability of the glenohumeral joint or functional scapulothoracic instability) ensues.<sup>4,10</sup> Thus, the role of the scapula in upper extremity function must be considered in any shoulder rehabilitation program.

Address correspondence to Michael L. Voight, DPT, OCS, SCS, ATC, Belmont University, School of Physical Therapy, 1900 Belmont Blvd, Nashville, TN 37212. E-mail address: Voightm@mail.belmont.edu

## THE ROLE OF THE SCAPULA

The scapula performs 3 major roles in the production of smooth, coordinated movement about the shoulder girdle. These roles are interrelated to maintain the glenohumeral relationship and provide a stable base for muscular function.

The first role of the scapula is the maintenance of dynamic stability with controlled mobility at the glenohumeral joint. In order to maintain itself as the stable platform for glenohumeral function, the scapula must move in a coordinated fashion with the moving humerus, so that the humeral head is constrained within the glenoid throughout the full range of shoulder motion.<sup>11</sup> The maintenance of proper alignment of the glenoid fossa not only allows for optimal bony constraint but also facilitates muscular constraint by maintaining proper length-tension relationships for efficient contraction of the rotator cuff muscles, thereby compressing the humeral head into the fossa.<sup>4,11</sup>

While maintaining dynamic stability, the scapular musculature must at the same time provide controlled mobility. During throwing motions, as the arm begins to accelerate, the scapula must be protracted in a smooth fashion laterally and then anteriorly around the thoracic wall to allow the scapula to maintain a normal positional relationship with the humerus. This motion is controlled through eccentric contraction of the medial-stabilizing musculature (mainly the rhomboids and the middle trapezius), thus facilitating the dissipation of some of the deceleration forces that occur in the follow-through phase.<sup>11</sup>

The scapula must also rotate upward with overhead activities to clear the acromion from the rotator cuff.<sup>12</sup> In normal abduction, the scapula moves laterally in the first 30° to 50° of abduction. As abduction continues, the scapula then rotates about a fixed axis through an arc of approximately 65° as the shoulder reaches full elevation.<sup>13</sup> This motion accounts for the 2:1 ratio between glenohumeral abduction and scapulothoracic rotation observed with overhead activity.<sup>14</sup> Upward rotation and elevation are required in order to tilt the acromion upward, hence decreasing the likelihood of impingement and coracohumeral arch compression.

The second role the scapula plays is as a base for muscle attachment. The muscles that stabilize the scapula attach to the medial border of the scapula, thereby controlling its position. This musculature controls scapular motion mainly through synergistic cocontractions and force couples, which are paired muscles that control the movement or position of a joint or a body part.<sup>7,15-17</sup> The main functions of these force couples are to obtain maximal congruency between the glenoid fossa and the humeral head, to provide dynamic glenohumeral stability, and to maintain optimal length-tension relationships.<sup>4,6,9</sup> The appropriate force couples for scapular stabilization include the upper and lower portions of the trapezius muscle working together with the rhomboid muscles, paired with the serratus anterior muscle.<sup>2,7</sup> The appropriate force couples for acromial elevation are the lower trapezius and the serratus anterior working together, paired with the upper trapezius and rhomboid muscles.<sup>2,7</sup>

In addition to acting as scapular stabilizers, muscles that attach along the lateral border of the scapula perform gross motor activities of the glenohumeral joint. The muscles of the rotator cuff attach along the entire surface of the scapula and are aligned so that their most efficient stabilizing activity occurs with the arm between 70° and 100° of abduction.<sup>10</sup>

Kibler<sup>7</sup> described these muscles working in this manner as a "compressor cuff," compressing the humeral head into the socket.

The third role of the scapula is best represented as the link in the proximal-to-distal transfer of energy that allows for the most appropriate shoulder positioning for optimal function.<sup>14,18-20</sup> The scapula is pivotal in transferring the large forces and high energy from the major sources for force and energy—the legs and trunk—to the actual delivery mechanism of the energy and force—the arms and hands.<sup>9,18,20</sup> Forces generated in the proximal segments must be transferred efficiently and regulated as they funnel through the shoulder to the hand.<sup>7</sup> These actions can be accomplished most effectively through the stable and controlled platform of the scapula, so that the entire arm rotates as a unit around the stable base provided by the scapulothoracic and the glenohumeral joints.

## PATHOMECHANICS

Most of the abnormal biomechanics and overuse injuries that occur about the shoulder girdle can be traced to alterations in the function of the scapular-stabilizing muscles.<sup>17,21</sup> Injury occurs to muscles through either direct macrotrauma or microtrauma. In addition, the musculature can be inhibited by painful conditions about the underlying joint. Muscle weakness is a common finding about the shoulder girdle, and decreased support of the shoulder due to weakness in any shoulder muscle could lead to pathology.<sup>1,4,22-24</sup> Weakness of the scapulothoracic muscles potentially leads to abnormal positioning of the scapula, disturbances in scapulohumeral rhythm, and generalized shoulder dysfunction.<sup>4</sup>

The most common weak or inhibited muscles are the lower stabilizers of the scapula (serratus anterior, rhomboids, middle and lower trapezii).<sup>11,22,23,25,26</sup> The serratus anterior and lower trapezius form an important force couple that produces acromial elevation. If part of that force couple is negated through either fatigue or nerve palsy, movement is abnormal. For example, paralysis of the serratus anterior results in reductions in both glenohumeral flexion and abduction. The medial border of the scapula is elevated off the rib cage, resulting in decreased acromial elevation. This problem manifests itself through decreased shoulder abduction and secondary impingement.<sup>4</sup> This lack of acromial elevation and secondary impingement has been seen concomitant with many shoulder problems. Most shoulder injuries incurred as a result of sports activities can be traced to abnormal biomechanics, which, in turn, can be related to improper functioning of the scapular muscles.<sup>7</sup> In fact, scapular instability is found in as many as 68% of rotator cuff problems and 100% of glenohumeral instability problems.<sup>7,27</sup> The abnormal scapular biomechanics that occur as a result of dysfunction create abnormal scapular positions that decrease normal shoulder function and predispose the shoulder to injury.<sup>7,21,26-28</sup>

The effects of muscle fatigue with regard to scapular stability have also been investigated. Thomson and Mitchell<sup>28</sup> investigated the effect of repetitive exercise on the scapular stabilizers by studying the ability of the scapular musculature to stabilize the scapula after fatiguing exercise in the proprioceptive neuromuscular facilitation (PNF) D2 pattern as measured by the lateral scapular slide (LSS) test. Their results suggest that a fatigue-induced strength deficit of the shoulder musculature can have an adverse effect on scapular positioning by allowing the scapula to glide more laterally during func-

tional activities.<sup>28</sup> The effect of fatiguing exercise on shoulder muscles has also been studied by Carpenter et al<sup>29</sup> and Voight et al,<sup>30</sup> who investigated the effects of exercise and muscle fatigue on shoulder proprioception. Both groups found a significant decrease in joint kinesthesia, measured using the time threshold to detection of passive movement after fatiguing exercise.<sup>29</sup> They hypothesized that a decrease in position sense as a result of fatigue of the shoulder girdle musculature could interfere with normal coordination and joint stability, thus impairing function around the shoulder girdle.<sup>29,30</sup>

## EVALUATION

The evaluation of scapular function is critical to overall success in managing injuries of the shoulder girdle and upper extremity. Several different methods evaluate scapular function. The first step in the evaluation process is to observe the scapula, both statically and dynamically, in relation to its role in the entire kinetic chain.

Static scapular position in the resting position can be observed from behind the patient for abnormalities such as winging or decreased elevation (Figures 1 and 2). The examiner should look for asymmetry, deformity, atrophy or hypertrophy, edema, tenderness, crepitation, and color and temperature changes to help confirm shoulder injury.<sup>5</sup> Static positional abnormalities can be further accentuated by having the individual isometrically contract the stabilizing musculature around the scapula.

Dynamic scapular movement can be evaluated by having the athlete slowly raise and lower the arm in both flexion and abduction. Look for smooth, controlled movement during both the ascending and descending phases of the motion, because scapular dyskinesis is often seen only during the lower, or eccentric, phase of the motion. In addition, during dynamic testing, a frequent finding is excessive lateral sliding of the scapula of an injured shoulder, as evidenced by an increased distance between the medial border of the scapula and the spinous processes of the vertebral column, as compared with the contralateral side.<sup>5</sup>

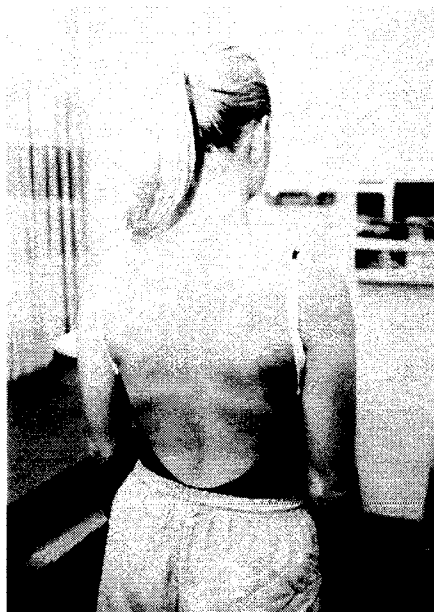

Figure 1. Normal scapular positioning.



Figure 2. Scapular winging.

Kibler<sup>7</sup> described a good provocative maneuver to evaluate scapular muscle strength. The patient is asked to perform an isometric pinch of the scapulae in retraction and hold this position for 15 to 20 seconds. Scapular muscle weakness results in a burning pain in less than 15 seconds.<sup>7</sup> However, in order to validate or properly objectify scapular muscle weakness (with numeric measurements), either manual muscle testing or the LSS test may be used.

Manual muscle testing of each of the individual muscles acting on the scapula has been commonly used in clinics to evaluate shoulder dysfunction. Yet, when done properly, manual muscle testing of each muscle can become very time consuming. Because of this, Kibler has developed the less time-consuming LSS test to evaluate scapular stability. This test compares the distance between a fixed point on the vertebral column and the scapula on the affected side (in specific positions) with that of the unaffected side as varying amounts of loads are placed on the supporting musculature.<sup>7,9,12,31,32</sup>

The LSS test begins with the establishment of a measurement reference point on the nearest spinous process to the inferior angles of the scapula (Figure 3A).<sup>9</sup> With the athlete's arms at the sides in the anatomical resting position, the distance from the inferior angle of the involved and the uninvolved scapula is measured from the reference point and compared. Kibler's second position of measurement is with the patient's hands on the hips, with the fingers anterior and the thumb posterior (Figure 3B).<sup>9</sup> This position places the humerus in approximately 45° of abduction. Because the second position of measurement is a transitional, graded progression of difficulty to the scapular-stabilizing musculature, many examiners jump directly to the third measurement position of 90° of arm elevation with maximal internal rotation (thumb to floor) at the glenohumeral joint (Figure 3C).<sup>9</sup> Measurements are again taken from the reference spinous process to the inferior angles of the involved and uninvolved scapulae. This final position presents a challenge to the scapular-stabilizing muscles in a much more functional position. For purposes of clinical evaluation, Kibler<sup>9</sup> initially recognized a 1-cm difference as clin-

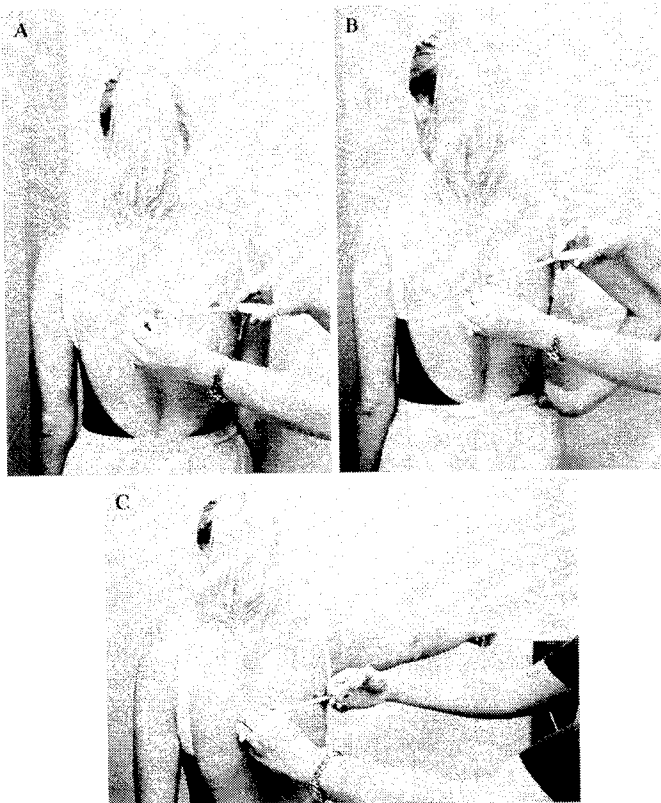


Figure 3. Lateral scapular slide test. A, Position 1. B, Position 2. C, Position 3.

ically significant.<sup>9</sup> Recently, he has increased this threshold of abnormality to 1.5 cm.<sup>7</sup> When pathology is present, it is not unusual to have asymmetry of as much as 3 cm.

Several studies have been performed to determine the reliability and validity of the LSS test, in which investigators have looked at the accuracy of marking the inferior angle of the scapula in different positions of abduction in comparison with radiographic examination (S.R. Tippett, unpublished data, 1991).<sup>7,33,34</sup> The radiographic comparison for the validity of the lateral scapular glide measure was found to have a correlation coefficient of more than 0.90.<sup>7</sup> Reliability has been established at between 0.80 and 0.88 and between 0.77 and 0.85 for intertester and intratester measurement (depending on the position), respectively (S.R. Tippett, unpublished data, 1991).<sup>7,33,34</sup> Test-retest reliability is greatest with the arm at the side and progressively decreases with increasing shoulder abduction. The third position (90° of abduction) is the most difficult to measure accurately because of muscle activity, and yet, this position achieved test-retest and intertester reliability of more than 0.78.<sup>6</sup> Therefore, it appears that the LSS test (1) reproduces the desired scapular points and the desired measurements, (2) is a reliable test in terms of reproducibility, and (3) tests muscles that are actually working to stabilize the scapula.<sup>7</sup>

## REHABILITATION

Once the complete and accurate diagnosis of all factors causing or contributing to scapular and shoulder problems is established, scapular rehabilitation should address all the functional roles of the scapula.<sup>1,7,11,17,32</sup> To accomplish this, the



Figure 4. Scapular clock. A, Protraction. B, Retraction.

clinician must first evaluate the patient and determine the exact cause of the patient's dyskinesia, keeping in mind that an injury is often the result of shoulder dyskinesia rather than direct trauma. Once the pathology is diagnosed, motion must be restored. Proper form and scapular control should also be emphasized. At this stage, care is taken to exercise the patient in ranges of motion that are not impinging muscles and to avoid fatiguing muscles to the point that proper scapular positioning and control cannot be maintained.<sup>28</sup> As motion is restored to larger pain-free ranges, strengthening is incorporated into the program. Finally, as full, pain-free motion is restored and strength progresses, return to sport or work activities can begin. In many cases, shoulder dysfunction can

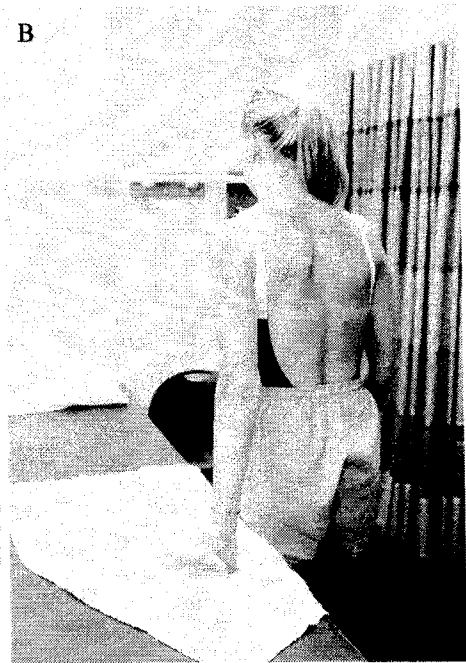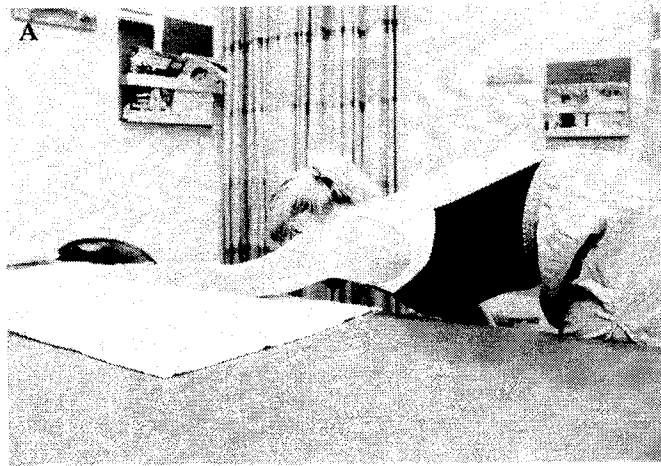


Figure 5. Towel slide. A, Beginning position. B, Ending position.



Figure 6. Standing weight shift.

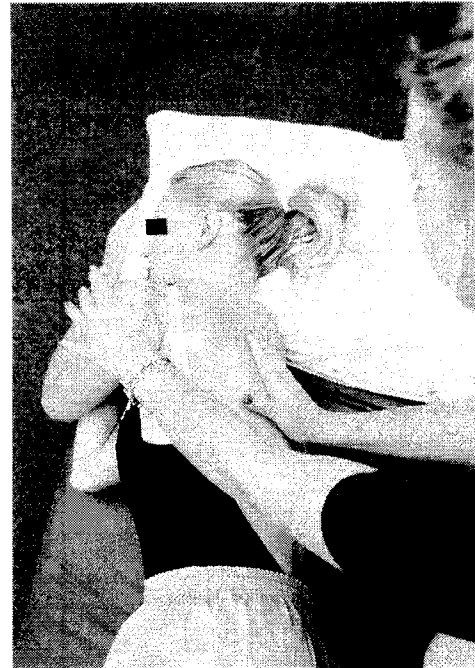


Figure 7. Scapular PNF.

be corrected by proper scapular muscular re-education and conditioning. By restoring normal scapular mechanics and force couples, rehabilitation can improve scapular position and motion to decrease impingement and increase rotator cuff efficiency.

Keeping in mind the ultimate goal of full, pain-free motion with proper scapular stabilization and positioning, the clinician can design many exercise variations from a few core exercises (Lexington Clinic Sports Medicine Center, unpublished data, 1999). Being aware of the role of the scapula in upper extremity function is important when designing upper extrem-

ity exercises. First and foremost, all the exercises must integrate scapular-stabilization techniques in order to keep the scapula in the proper position to prevent impingement and maintain length-tension relationships of the musculature (Lexington Clinic Sports Medicine Center, unpublished data, 1999).

Every exercise progression must begin with stretching exercises. Weak muscles cannot be strengthened if their antagonistic counterparts are not stretched<sup>22</sup> (Lexington Clinic Sports Medicine Center, unpublished data, 1999). Thus, it is important to stretch anterior chest muscles, such as the pectoralis major and minor and others that contribute to the rounded-shoulder



**Figure 8. Lawnmower exercise. A, Starting position. B, Ending position.**

posture, which inhibits scapulohumeral rhythm<sup>22</sup> (Lexington Clinic Sports Medicine Center, unpublished data, 1999). With a correct posture, facilitated by stretching, restoration of motion and scapular-strengthening exercises can begin. Some core techniques that can be used to restore motion and scapular stability are the scapular clock, towel slide, standing weight shift with the Pro Fitter (Fitter International Inc, Calgary, Alberta, Canada) scapular PNF patterns, and lawnmower exercises.

1. In the scapular-clock exercise, the patient envisions a clock tattooed on the injured shoulder. The patient places the hand of the injured arm on a ball on a plinth. The patient then

moves the shoulder in the direction of the 12 o'clock, 3 o'clock, 6 o'clock, and 9 o'clock positions, which facilitates elevation, retraction, depression, and protraction of the scapula, respectively (Figure 4).

2. In the towel slide, the patient stands near a plinth with the hand of the injured arm on a towel on the plinth at the side. Instruct the patient to forward flex at the hips (while keeping the thoracic spine in relative extension) such that shoulder flexion is induced, producing a light stretch. Then instruct the patient to straighten up and extend the shoulder. When the shoulder is fully extended, instruct him or her to concentrate on "pinching" the scapulae together to facilitate the rhomboids and lower trapezius muscle (Figure 5), (Lexington Clinic Sports Medicine Center, unpublished data, 1999).
3. For the Pro Fitter standing weight shift, the patient stands with the hands placed on the Pro Fitter. Instruct the patient to lean forward and shift weight from the right upper extremity to the left upper extremity. This facilitates motion, proprioception, and scapular stabilization (Figure 6).<sup>35</sup>
4. For scapular PNF patterns, the patient lies on the noninjured side or stands. Instruct the patient to resist motion as the scapula is elevated and protracted and depressed and retracted (Figure 7).<sup>1</sup>
5. The lawnmower exercise, which simulates pulling the starter cord of a lawnmower, has wide-ranging variability. It can be used from very early in rehabilitation to facilitate motion by having the patient "pull," using large amounts of trunk rotation and lower extremity extension to guide shoulder motion. It can be progressed in the intermediate stage by adding dumbbells and decreasing the amount of trunk rotation produced and then to the advanced stage by adding Thera-Band (Quality Health Products, Inc, Indiana, PA) or tubing, minimizing trunk motion, and adding lower extremity movement such as stepping or lateral lunging (Figure 8). (Lexington Clinic Sports Medicine Center, unpublished data, 1999).



**Figure 9. Ball stabilization on the wall.**

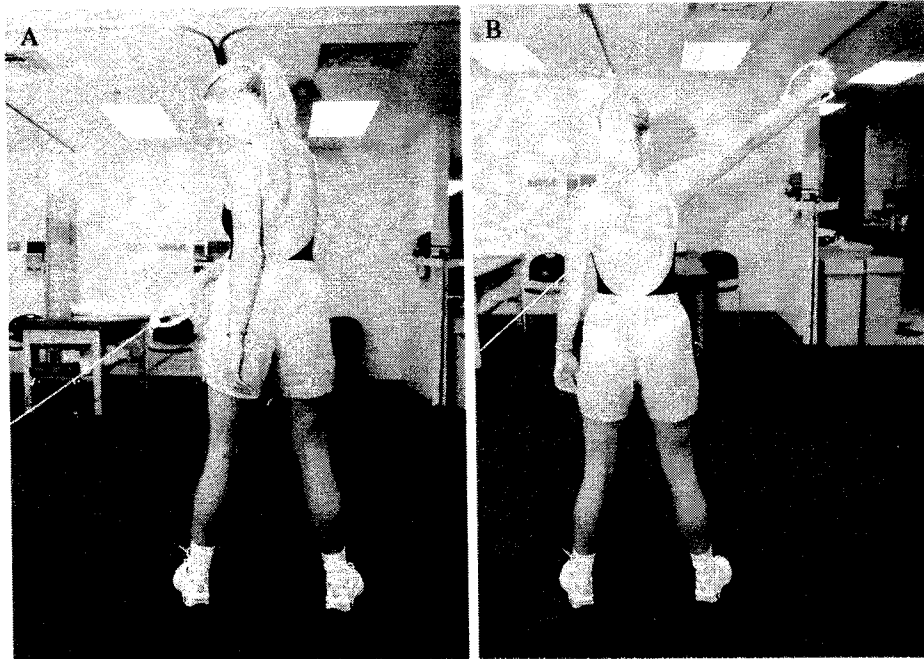


Figure 10. Proprioceptive neuromuscular facilitation (PNF) D2 pattern. A, Starting position. B, Ending position.



Figure 11. Alternating serratus anterior punches. A, Starting position. B, Ending position.



Figure 12. Plyoball exercise. A, Starting and ending position. B, Throwing.

Although few researchers have studied multiplanar exercises, Davies and Dickoff-Hoffman<sup>36</sup> determined that the PNF D2 pattern (shoulder flexion, abduction, and external rotation) can be used to mimic functional directionality and facilitate triplanar conditioning, with either manual resistance or surgical tubing. They recommended performing this exercise to the point of fatigue or until the athlete loses the ability to maintain the shoulder in a 90° abducted position.<sup>36</sup>

Other studies have focused on exercise applications for rehabilitation. Moseley et al<sup>17</sup> conducted electromyographic testing of scapular muscles during shoulder rehabilitation to determine how scapular muscles could best be exercised in a rehabilitation program. The upper, middle, and lower trapezii; levator scapulae; rhomboid major; middle and lower serratus anterior; and pectoralis minor were tested. Subjects performed each of 16 exercises concentrically, isometrically, and then eccentrically.<sup>17</sup> Moseley et al<sup>17</sup> determined that rowing, hori-

zontal abduction in neutral, and horizontal abduction with the humerus in external rotation were the primary exercises that focused on scapular retraction. Rowing and horizontal abduction in neutral both optimally exercised all 3 parts of the trapezius, the levator scapulae, and the rhomboids. Horizontal abduction with humeral external rotation exercised the same muscles, except for the rhomboids. The authors concluded that rowing was the ideal exercise for scapular retractors, because it allowed for the greatest range of scapular retraction and had a greater intensity of muscle activity.<sup>8,17</sup>

The exercise program should be progressed creatively. As the patient's pain-free range of motion improves, more emphasis should be placed on strengthening the scapular musculature to improve stabilization and retraction. The following exercises improve the position of the scapula on the thorax, facilitate scapulohumeral rhythm, and decrease the likelihood of impingement.

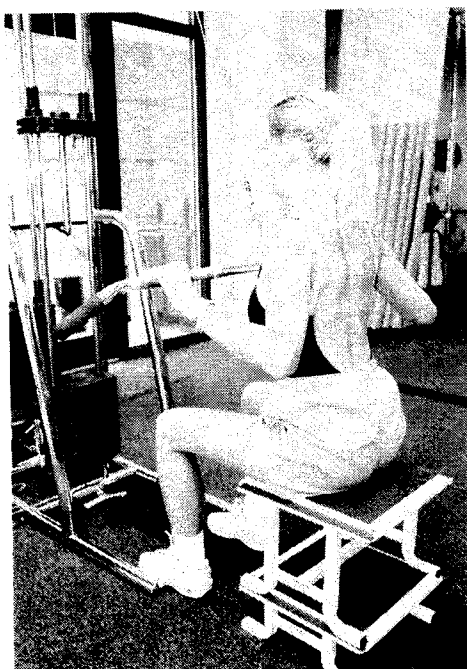


Figure 13. Latissimus pull-down: ending position.

1. Ball-stabilization exercises can begin very early in the rehabilitation process and progress throughout the course of treatment. The patient should stand near a plinth with the injured side's hand on a ball. Instruct the patient to prevent the ball from moving as perturbations are applied in various directions. Perturbations in multiple directions work the rotator cuff, and perturbations in planar directions strengthen various scapular stabilizers. This exercise can be progressed by providing larger perturbations, then by placing the ball on a wall, and then by increasing the weight of the ball (Figure 9). (Lexington Clinic Sports Medicine Center, unpublished data, 1999).
2. The PNF D2 pattern exercise can mimic functional directionality and facilitate triplanar conditioning. This exercise can be progressed by using dumbbells, tubing, or Thera-Band to make it a plyometric exercise. Trunk extensions and lower extremity stepping are very effective in facilitating increased scapular retraction (Figure 10)<sup>35</sup> (Lexington Clinic Sports Medicine Center, unpublished data, 1999).
3. Alternating serratus anterior punches with a tubing system strengthens the often-neglected serratus anterior muscle(s), as well as the rotator cuff muscles. This exercise can also be used for increasing range of motion and strengthening throughout the course of treatment. Begin static-stance punching with light dumbbells and progress to stepping alternating punches with a tubing system or Thera-Band (Figure 11)<sup>1</sup> (Lexington Clinic Sports Medicine Center, unpublished data, 1999).
4. Plyometric exercises using weighted balls with a Plyoback (AliMed Inc, Dedham, MA) provide a good progression to improve scapular stability. This exercise facilitates range of motion, stability, and strengthening. Throwing the ball in different directions (ie, overhead soccer throw, twisting throw, and unilateral arm throw) activates different muscles and provides variety and progression (Figure 12).<sup>1</sup>
5. Latissimus pull-downs are another versatile exercise for an important scapular-stabilizing muscle. The seated patient

pulls the resistance down to the chest (Figure 13). Instruct the athlete to observe proper posture and exaggerate "pinching" the scapulae together. Progress to alternating arm pull-downs to the chest, then to other weight equipment. The exercise can also be made more challenging by altering the direction of the pull. Finally, the patient can begin the exercise with trunk forward flexion and shoulder flexion and extend the trunk while pulling down. Trunk extension facilitates scapular retraction (Lexington Clinic Sports Medicine Center, unpublished data, 1999).

These exercises will not be beneficial for every patient treated. Clinicians are cautioned to avoid using this article as a protocol or "cookbook." Instead, experiment with the exercise suggestions and develop different techniques for facilitating scapular retraction and stabilization. All the exercises can and should be varied in many ways. Clinicians should challenge themselves to be creative and experiment with different forms of every exercise in order to achieve each individual patient's rehabilitative goals. Individualize the treatment for each patient's pathologies and make rehabilitation fun and exciting.

## CONCLUSIONS

The shoulder must be considered a kinetic chain made up of several joints. The normal function of the scapula and surrounding musculature is vital to the overall normal function of the shoulder. Rotator cuff strengthening has been an obvious treatment for various pathologies. Since the origins of the rotator cuff muscles arise from the scapula, an effective exercise regime for rehabilitation should include improving the strength and function of the muscles that control the position of the scapula. Weakness of these anchoring muscles may lead to altered biomechanics of the glenohumeral joint, with resultant excessive stress imparted to the rotator cuff and anterior capsule. Advancements in the knowledge of biomechanics and electromyographic patterns of the shoulder have allowed us to develop strengthening exercises that maximally strengthen these "anchor" muscles.

## ACKNOWLEDGMENTS

We credit the entire staff of the Lexington Clinic Sports Medicine Physical Therapy Department in Lexington, KY. Special thanks to Keith Duerler, Robin Cromwell, and John McMullen. Their expertise in scapular rehabilitation and the use of their clinic for research are greatly appreciated.

## REFERENCES

1. Paine RM, Voight ML. The role of the scapula. *J Orthop Sports Phys Ther.* 1993;18:386-391.
2. Peat M. Functional anatomy of the shoulder complex. *Phys Ther.* 1986;66:1855-1865.
3. Bigliani LU, Codd TP, Connor PM, Levine WN. Shoulder motion and laxity in the professional baseball player. *Am J Sports Med.* 1997;25:609-613.
4. Kamkar A, Irrgang JJ, Whitney SL. Nonoperative management of secondary shoulder impingement syndrome. *J Orthop Sports Phys Ther.* 1993;17:212-224.
5. Pink M, Jobe FW. Shoulder injuries in athletes. *Clin Manage.* 1991;11:39-47.
6. Jobe FW, Pink M. Classification and treatment of shoulder dysfunction in the overhead athlete. *J Orthop Sports Phys Ther.* 1993;18:427-432.

7. Kibler WB. The role of the scapula in athletic shoulder function. *Am J Sports Med.* 1998;26:325-337.
8. DiVeta J, Walker ML, Skibinski B. Relationship between performance of selected scapular muscles and scapular abduction in standing subjects. *Phys Ther.* 1990;70:470-476.
9. Kibler WB. Role of the scapula in the overhead throwing motion. *Contemp Orthop.* 1991;22:525-532.
10. Bak K, Faunt P. Clinical findings in competitive swimmers with shoulder pain. *Am J Sports Med.* 1997;25:254-260.
11. Pink M, Perry J. Biomechanics. In: Jobe FW, ed. *Operative Techniques in Upper Extremity Sports Injuries.* St Louis, MO: Mosby; 1996:109-123.
12. Kibler WB. Evaluation of sports demands as a diagnostic tool in shoulder disorders. In: Matsen FA, Fu F, Hawkins RJ, eds. *The Shoulder: A Balance of Mobility and Stability.* Rosemont, IL: American Academy of Orthopaedic Surgeons; 1993:379-395.
13. Poppen NK, Walker PS. Normal and abnormal motion of the shoulder. *J Bone Joint Surg Am.* 1976;58:195-201.
14. Kennedy K. Rehabilitation of the unstable shoulder. *Oper Techniq Sports Med.* 1993;1:311-324.
15. Bagg SD, Forrest WJ. Electromyographic study of the scapular rotators during arm abduction in the scapular plane. *Am J Phys Med.* 1986;65:111-124.
16. DiGiovine NM, Jobe FW, Pink M, Perry J. An electromyographic analysis of the upper extremity in pitching. *J Shoulder Elbow Surg.* 1992;1:15-25.
17. Moseley JB Jr, Jobe FW, Pink M, Perry J, Tibone JE. EMG analysis of the scapular muscles during a shoulder rehabilitation program. *Am J Sports Med.* 1992;20:128-134.
18. Elliott BC, Marshall R, Noffal G. Contributions of upper limb segment rotations during the power serve in tennis. *J Appl Biomech.* 1995;11:433-442.
19. Fleisig GS, Dillman CJ, Andrews JR. Biomechanics of the shoulder during throwing. In: Andrews JR, Wilk KE, eds. *The Athlete's Shoulder.* New York, NY: Churchill Livingstone; 1994:355-368.
20. Kibler WB. Biomechanical analysis of the shoulder during tennis activities. *Clin Sports Med.* 1995;14:79-85.
21. Kuhn JE, Plancher KD, Hawkins RJ. Scapular winging. *J Am Acad Orthop Surg.* 1995;3:319-325.
22. Janda V. Muscles and cervicogenic pain syndromes. In: Grant R, ed. *Physical Therapy of the Cervical and Thoracic Spine.* New York, NY: Churchill Livingstone; 1988:153-166.
23. Janda V. The relationship of shoulder girdle musculature to the etiology of cervical spine syndromes. Presented at: Proceedings of an International Conference on Manipulative Therapy; 1983; Perth, Western Australia.
24. Jull GA, Janda V. Muscles and motor control in low back pain: assessment and management. In: Twomey LT, Taylor JR, eds. *Physical Therapy of the Low Back.* New York, NY: Churchill Livingstone; 1987:253-278.
25. Hammer WI. Muscle imbalance and postfacilitation stretch. In: Hammer WI, ed. *Functional Soft Tissue Examination and Treatment by Manual Methods.* Gaithersburg, MD: Aspen; 1999:415-445.
26. Glousman R, Jobe FW, Tibone JE, Moynes D, Antonelli D, Perry J. Dynamic electromyographic analysis of the throwing shoulder with glenohumeral instability. *J Bone Joint Surg Am.* 1988;70:220-226.
27. Warner JJ, Micheli LJ, Arslenian LE, Kennedy J, Kennedy R. Scapulothoracic motion in normal shoulders and shoulders with glenohumeral instability and impingement syndrome: a study using Moire topographic analysis. *Clin Orthop.* 1992;285:191-199.
28. Thomson BC, Mitchell RS. The effects of repetitive exercise of the shoulder on lateral scapular stability. Presented at: American Physical Therapy Association Combined Sections Meeting; February 2000; New Orleans, LA.
29. Carpenter JE, Blasler RB, Pellizon GG. The effects of muscle fatigue on shoulder joint position sense. *Am J Sports Med.* 1998;26:262-265.
30. Voight ML, Hardin JA, Blackburn TA, Tippett SR, Canner GC. The effects of muscle fatigue on and the relationship of arm dominance to shoulder proprioception. *J Orthop Sports Phys Ther.* 1996;23:348-352.
31. Kibler WB. Clinical examination of the shoulder. In: Petrone FA, ed. *Athletic Injuries of the Shoulder.* New York, NY: McGraw-Hill; 1995: 31-41.
32. Kibler WB, Livingston B, Bruce R. Current concepts in shoulder rehabilitation. *Adv Oper Orthop.* 1995;3:249-300.
33. Odom CJ, Hurd CE, Denegar CR. *Intratester and Intertester Reliability of the Lateral Scapular Glide Test* [dissertation]. Slippery Rock, PA: Slippery Rock University; 1994.
34. Tippett SR. *Reliability of the Lateral Scapular Glide Test* [dissertation]. Champaign, IL: Illinois State University; 1994.
35. Gowan ID, Jobe FW, Tibone JE, Perry J, Moynes DR. A comparative electromyographic analysis of the shoulder during pitching: professional versus amateur pitchers. *Am J Sports Med.* 1987;15:586-590.
36. Davies GJ, Dickoff-Hoffman S. Neuromuscular testing and rehabilitation of the shoulder complex. *J Orthop Sports Phys Ther.* 1993;18:449-458.