

# PATELLAR REALIGNMENT IN THE SKELETALLY IMMATURE

LYLE J. MICHELI, MD, BRYAN K. MATANKY, MD, and DONALD D. DIVERIO, Jr, DO

Mechanical derangements of the patellofemoral joint in the growing child may be insidious in onset. These derangements often result from a variety of genetic or developmental factors or occur from acute trauma, with partial or complete displacement of the patella from the trochlear groove. In children or adolescents with derangements of patellofemoral congruence unresponsive to therapeutic exercise or mobilization techniques, surgical intervention may be necessary. In contrast to adults, techniques for realignment must not violate the proximal tibial physis or tubercle, which is contiguous with this physis, thus limiting these procedures to "soft-tissue" techniques. The indications for surgical intervention in this age group are defined, and the surgical interventions available, including lateral retinacular release, proximal quadricepsplasty, distal tenodesis of the patella, and distal redirection of the patellar tendon.

**KEY WORDS:** patellofemoral, child, surgical repair

The patellofemoral joint is a common source of pediatric and adolescent disability. It is vulnerable to traumatic disorders as well as congenital and developmental abnormalities. The unique anatomy and changing physiology of the developing knee may pose problems in the proper diagnosis and treatment of these disorders. Pain or disability can derive from the periarticular soft tissue, the osseous structures, or the articular or physeal cartilage. Therefore, great care must be taken initially, in forming the proper diagnosis in these patients. Once the diagnosis is reached, treatment must involve an understanding of the plasticity of the patellofemoral joint with growth. A thorough understanding of the basic anatomy of the developing knee is mandatory in diagnosing and treating disorders of the patellofemoral joint in this age group.

Merchant's<sup>10</sup> classification of patellofemoral disorders (Table 1), although useful, does not adequately address the pediatric knee. Absent from this classification is a discussion of the genetic, congenital, developmental, and posttraumatic acquired disorders. These categories, combined with Merchant's classification, provide a comprehensive framework from which to discuss abnormalities of the pediatric knee.

## ANATOMY AND DEVELOPMENT

By the eighth week of gestation, the human knee begins to take on the recognizable form representing the structures of the adult knee. During the prenatal and infancy

periods, the growth of the human knee is rapid. During childhood, growth increases occur at a slowly declining rate until the onset of puberty when growth accelerates during the adolescent "growth spurt," before slowing and ending.<sup>1</sup>

The patella is a sesamoid bone lying within the extensor mechanism of the knee. Ossification, although variable, generally begins by age 4 but can be delayed in the setting of patellofemoral derangement. The articular surface is divided into medial, lateral, and odd facets. The proximal two thirds articulates with the trochlear facets and supratrochlear regions of the distal femur, whereas the distal one third is extra-articular.

The articular portion of the distal femur includes the femoral condyles and their contiguous trochlear facets, which comprise the femoral component of the patellofemoral joint. The lateral trochlear facet projects further anteriorly and proximally than the medial facet.

In full extension, the patella rests in the supratrochlear fossa. At this point, patellofemoral contact is largely along the lateral surface. As the knee flexes, the medial patellar facet comes in contact with the trochlear groove. During flexion and extension, the patella moves 7 to 8 cm relative to the femur.

The soft-tissue structures of the extensor mechanism provide both passive and dynamic forces, stabilizing the patella during motion. Medially, the patellofemoral and meniscopatellar ligaments provide passive support to the patella. The vastus medialis and vastus medialis obliquus muscles both offer dynamic support. The lateral patellofemoral band has attachments to the iliotibial band and lateral intermuscular septum, thus passively directing the patella posteriorly and laterally during knee flexion. The vastus lateralis and vastus lateralis obliquus muscles both provide dynamic lateral stabilizing force.

Alterations in the development of the lower limb can adversely affect the mechanics of the patellofemoral joint. Additionally, during pubescence, the differential rate of growth of bones and soft tissues may lead to excessive

From the Division of Sports Medicine and Department of Orthopaedic Surgery, The Children's Hospital, Boston, MA, and Harvard Medical School, Boston, MA.

Address reprint requests to Lyle Micheli, MD, Director, Division of Sports Medicine, The Children's Hospital, 300 Longwood Ave, Boston, MA 02115.

Copyright © 1994 by W. B. Saunders Company  
1060-1872/94/0204-0011\$05.00/0

**TABLE 1. Classification of Patellofemoral Disorders**

- I. Trauma (conditions caused by trauma in the otherwise normal knee)
  - A. Acute trauma
    1. Contusion (hematoma)
    2. Fracture
      - a. Patella (bipartite)
      - b. Femoral trochlea
      - c. Proximal tibial epiphysis (tubercle)
    3. Patellar dislocation
    4. Rupture
      - a. Quadriceps tendon
      - b. Patellar tendon
  - B. Repetitive trauma (overuse syndromes)
    1. Patellar tendinitis (jumper's knee)
    2. Quadriceps tendinitis
    3. Peripatellar tendinitis (anterior knee pain of adolescence due to hamstring contracture)
    4. Peripatellar bursitis
    5. Apophysitis
      - a. Osgood-Schlatter disease
      - b. Sinding-Larsen-Johansson disease
  - C. Late effects of trauma
    1. Posttraumatic chondromalacia patellae
    2. Posttraumatic patellofemoral arthritis
    3. Anterior fat-pad syndrome (posttraumatic fibrosis)
    4. Reflex sympathetic dystrophy of the patella
    5. Patellar osseous dystrophy
    6. Acquired patellar infera
    7. Acquired quadriceps fibrosis
- II. Patellofemoral dysplasia
  - A. Lateral patellar compression syndrome
    1. Secondary chondromalacia patellae
    2. Secondary patellofemoral arthritis
  - B. Chronic subluxation of the patella
    1. Secondary chondromalacia patellae
    2. Secondary chondromalacia arthritis
  - C. Recurrent dislocation of the patella
    1. Associated fractures
      - a. Osteochondral (intra-articular)
      - b. Avulsion (extra-articular)
    2. Secondary chondromalacia patellae
    3. Secondary patellofemoral arthritis
  - D. Chronic dislocation of the patella
    1. Congenital
    2. Acquired
- III. Idiopathic chondromalacia patellae
- IV. Osteochondritis dissecans
  - A. Patella
  - B. Femoral trochlea
- V. Synovial plica
  - A. Medial patellar (shelf)
  - B. Suprapatellar
  - C. Intrapatellar
  - D. Lateral patellar

(Reprinted with permission from Merchant AC: Classification of patellofemoral disorders. *Arthroscopy* 4:235, 1988.)

muscle tension.<sup>2</sup> Both of these factors can produce the "over-growth injuries."<sup>1</sup>

## CONGENITAL AND GENETIC DISORDERS

### Congenital Patellar Dislocation

Congenital dislocation of the patella has been reported infrequently in the literature. It may be bilateral or unilateral, reducible or irreducible, and is often diagnosed later because of a delay in patellar ossification. Factors related to its etiology include pathologic muscular attachments and the failure of the normal myotomal rotation of the lower extremity.<sup>3</sup> Early surgical treatment is recom-

mended to allow physiologic patellofemoral congruence to occur.<sup>4</sup> Soft-tissue procedures are recommended in the skeletally immature patient, but bony procedures may be necessary in the mature individual.

### Extensor Mechanism Duplication

Duplication of the extensor mechanism is a rare cause of patellofemoral disability. Duplication can involve either the sagittal or coronal planes, and treatment involves resection of the hypoplastic tissues and centralization of the remaining structures.<sup>5,6</sup>

### Multiple Epiphyseal Dysplasia (MED)

In addition to the more recognized orthopaedic manifestations of the MED syndrome, patellofemoral abnormalities are present in as many as 50% of patients.<sup>7</sup> Patellar duplication may occur and is treated by resection of the dysplastic structures.

### Nail-Patella Syndrome

In this autosomal dominant disorder, typical features include nail abnormalities, iliac horns, radial head hypoplasia, and absence of the patella. The patella may also show irregularities in shape or patella baja. Fortunately, disability referable to the extensor mechanism is generally mild.<sup>8</sup>

### Down's Syndrome

The generalized soft-tissue laxity and muscular hypotonia characteristic of this condition causes these patients to have a greater predilection for patellar subluxation or dislocation. Disability is generally not significant. For the symptomatic patient without secondary deformities, Mendez et al<sup>9</sup> recommend operative intervention.

### Developmental Patellofemoral Dysplasia

Patellofemoral dysplasia refers to a spectrum of anatomic abnormalities leading to anterior knee pain frequently associated with varying degrees of patellar instability. Anatomic factors predisposing an individual to patellar instability include an elongated patellar tendon, quadriceps weakness, a dysplastic patella or lateral femoral condyle, genu valgum, recurvatum, and joint laxity. Roentgenographic parameters of patellofemoral anatomy provide assistance in the documentation of dysplasia of the joint.<sup>10</sup> However, documentation of dysplasia does not seem to reliably predict the expression of symptoms. This appears to be multifactorial, consisting of environmental and developmental factors. The clinical expression of patellofemoral dysplasia demonstrates a continuum of syndromes based on history, physical examination, and 30° axial patellar radiographic findings.

### Lateral Patellar Compression Syndrome (LPCS)

LPCS is the development of activity-related anterior knee pain without patellar instability. The patient will complain of dull, aching anterior knee pain initiated by running, stair climbing, or prolonged sitting. An examination elicits variable palpatory tenderness in the retinacular tissue or patellar facets inferomedially or superolaterally. The lateral soft tissue restraints to the

patella are tight and the patella apprehension test is negative. Intra-articular effusions are rare. Radiographs may be negative or show patellar tilt, lateral facet sclerosis, or a decreased lateral patellofemoral joint space.

### Chronic Patellar Subluxation

Symptoms in this entity are similar to those in LPCS, but also include locking and giving way. The two syndromes may be differentiated by x-ray or physical findings of patellar subluxation. The patellar apprehension test is variable. Radiographic patellofemoral congruency measurements may show abnormal tilt or abnormal patellofemoral congruence (Fig 1).

### Recurrent Patellar Dislocation

This clinical entity is characterized by repeated episodes of giving way, locking, and effusions. Patella alta may be present, and the apprehension test is frequently positive. These patients may show evidence of progressive dysplasia and marked anatomic deficiency with both patellar and trochlear deformity. The differentiation between recurrent dislocation and chronic recurrent subluxation is a matter of degree. In recurrent dislocation, specific mechanical maneuvers by the patient or medical personnel are necessary to re-centralize the patella.

### Chronic Patellar Dislocation

The most advanced form of patellofemoral dysplasia, chronic patellar dislocation, can be acquired or congenital. Roentgenographs show the patellar dislocation as well as significant patellar dysplasia and a shallow or flat trochlear groove.

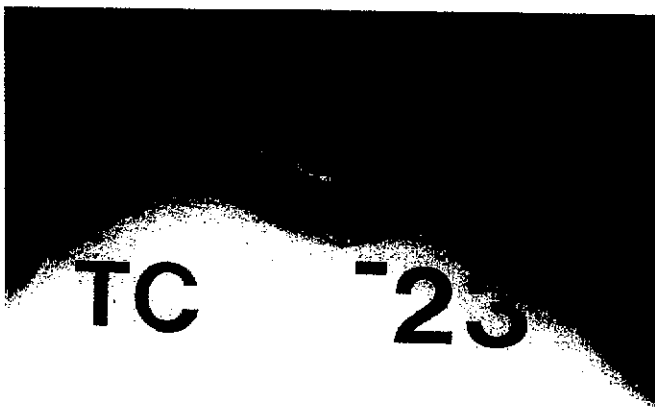


Fig 1. The Merchant, or skylline, radiographic view of the patellofemoral joint can assist in determining patellofemoral derangement. The patellar congruence measurement illustrated determines the medial or lateral deviation of the patella in the trochlear groove on the Merchant view.

### Acute Patellar Dislocation

Dislocation of the patella may occur in the setting of patellofemoral dysplasia,<sup>11</sup> in association with congenital, genetic, or neuromuscular diseases,<sup>12</sup> or it may occur in young athletes with normal patellofemoral anatomy subjected to a high impact to the medial patella, as in striking the boards in hockey or the court in basketball. The history will often show a twisting injury or a direct blow causing the knee "to pop out and go back in." The dislocated patella is often spontaneously reduced. When necessary, closed reduction is accomplished by flexing the hip, applying the appropriate directed force to the patella, and extending the knee. Most dislocations occur laterally, although medial dislocations have been reported. Radiographs should be obtained after the reduction to document any associated fractures, although these do not show all lesions (Fig 2, A and B). Computerized tomography and MRI are helpful in delineating osteochondral injuries. Unfortunately, significant chondral fractures of the patella or trochlear groove may be undetected by present imaging techniques (Fig 3). A rare type of patellar dislocation is an intra-articular dislocation.<sup>13,14</sup>

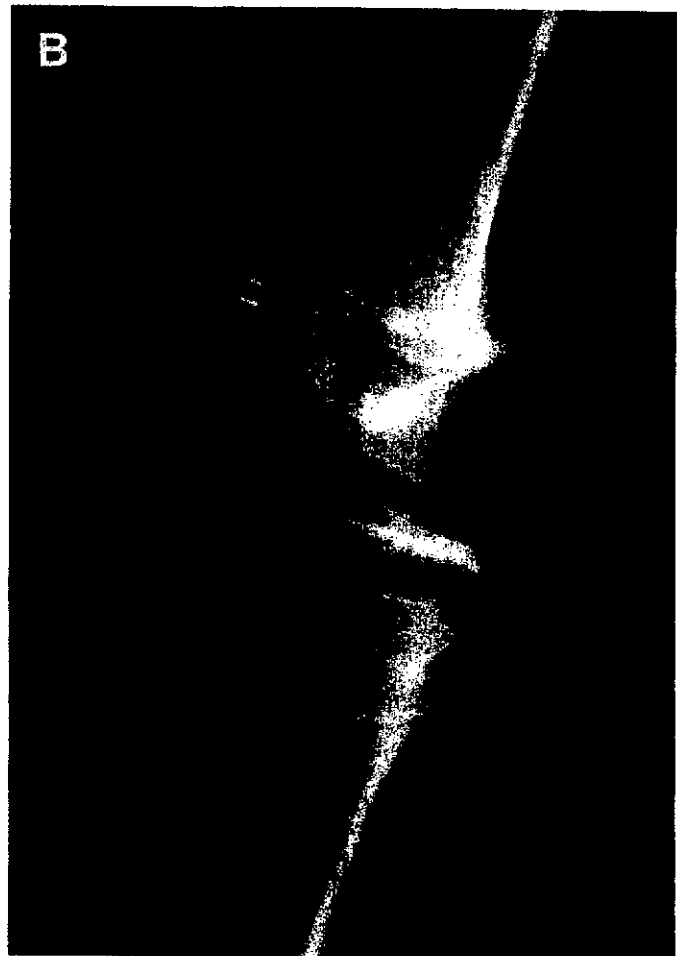
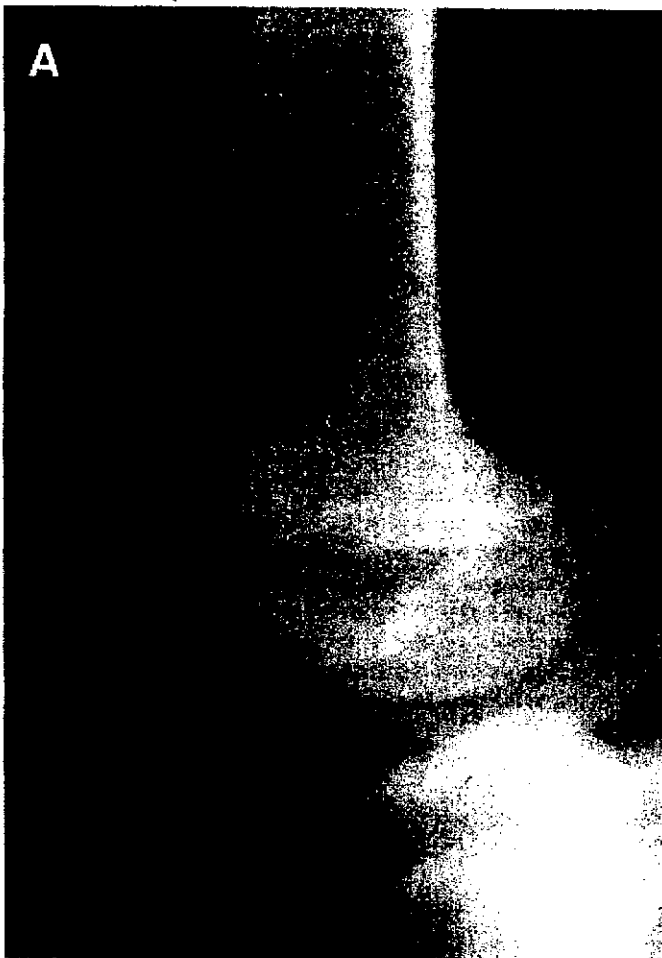### Overuse Syndromes

Merchant's classification of patellofemoral disorders lists the overuse syndromes. These occur secondary to chronic, repetitive microtrauma and are commonly seen in pediatric athletes. A number of factors play a role, and patellofemoral dysplasia is one. Treatment of these conditions is largely conservative and does not frequently require operative intervention. They are mentioned here as a reminder that they should be included in the differential diagnosis of patellofemoral pain.

### TREATMENT

Numerous studies outline the altered load distribution to the articular cartilage of the patella in normal and abnormal situations. Malposition of the patella caused by chronic changes or by an acute malposition will clearly alter the load distribution on the articular cartilage. Ficat and Hungerford<sup>15</sup> described lateral hyperpressure caused by lateral retinacular contracture. Under experimental conditions, articular cartilage degeneration has been produced by repetitive shear and compressive forces.<sup>16-18</sup> The articular cartilage of an adult does not appear to be capable of adequate repair once a significant injury has occurred.<sup>19</sup> The articular cartilage of a skeletally immature individual may react very differently. That cartilage may retain a much greater amount of regenerative ability and restore to a much greater degree, as noted by Ohno et al<sup>20</sup> in biopsies of patellar articular cartilage in adolescents with recurrent dislocations.

The natural history of abnormal mechanics and degeneration of the patellofemoral joint has been followed.




**Fig 2. (A) Acute dislocation of the patella in a young female soccer player required manipulative reduction. Postoperative radiographs showed a large osteochondral fracture of the patella. (B) Open reduction and fixation of the fragment, done at the time of arthroscopic-assisted lateral release and open medial retinacular plication.**

Karlson<sup>21</sup> observed 71 men with a clinical diagnosis of chondromalacia with a follow-up of 1 to 21 years. Eighty percent of these patients had continuing or worsening symptoms in this period of time. He noted that symptoms from chondromalacia may continue indefinitely without treatment.<sup>22</sup> In 1970, Bentley<sup>23</sup> recommended that patellae with lesions greater than 1.3 cm in diameter should be removed. In 1979, Maquet<sup>24</sup> investigated the mechanics of the patellofemoral joint and noted that in normal knees, the stress on the articular surface of the patella is proportional to the weight-bearing surface of that particular joint. When the mechanics are altered, the stresses are then concentrated to an abnormal region. If the patellofemoral articular pressure is either unevenly distributed or too high for the resistance of the tissues, osteoarthritis will then result.<sup>24</sup> Therefore, if the pathomechanics are left untreated, there can be persistent knee pain, disability, and progressive arthritis. These observations form the rationale for early treatment of patellofemoral dysplasia aimed at establishing patellofemoral congruency and thus diminishing peak articular contact forces.

Treatment of patellofemoral malalignment is directed at centralizing the patella. In the growing child or ado-

lescent, this can usually be accomplished by therapeutic exercise or mobilization. On occasion, these techniques must be supplemented by surgical releases of contracted tissues, plication of redundant tissues, or redirection of muscle-tendon forces. Specific exercises are usually directed at strengthening the medial musculature of the thigh and stretching tight iliotibial band, hamstrings, or lateral quadriceps.<sup>25</sup> The goals of these techniques are to mobilize the contracted passive patellar soft tissue restraints and to balance the quadriceps mechanism by strengthening the vastus medialis muscle. The program used in our clinic has as its foundation a static progressive resistive straight-leg raising exercise program. Significant resolution of symptoms was noted in 90% of patients who were able to perform three sets of 10 repetitions with 12 pounds of weight.<sup>26,27</sup> These leg lifts are performed daily with both legs, and the weight is added in 1- to 2-pound increments per week. This regimen does not allow dynamic resistance exercises until the 12-pound goal has been maintained for 3 months. These results for conservative management of anterior knee pain have been duplicated by many investigators<sup>28,29</sup> at an 80% to 90% success rate. Ten to 20% of patients will not succeed with this conservative regimen. This is be-



**Fig 3.** An adolescent male basketball player complained of a painful snap with knee flexion after a single acute dislocation of the patella. Three-week treatment consisted of immobilization and subsequent exercises. Radiographs and magnetic resonance images were not diagnostic. This photo taken at the time of arthroscopy shows a large chondral fracture at the junction of the central eminence and medial facet. Removal resulted in complete relief of symptoms.

cause of persistent incapacitating pain and is usually associated with inability to progress with strengthening or the development of patellar subluxation.

## SURGICAL TECHNIQUES

### Arthroscopic Percutaneous Lateral Patellar Retinacular Release

Our first line of surgical treatment will usually be an arthroscopic percutaneous lateral patellar retinacular release. This is specifically indicated in cases where the lateral retinaculum is tight as shown by physical examination and increased tilt on skyline view. This is performed for a skeletally immature patient with laterally subluxing or tilting patella who has failed an adequate trial of conservative management, usually for at least 3 months.

Under regional or general anesthesia and pneumatic tourniquet control, complete arthroscopic evaluation of the knee is performed through a standard anterolateral portal. Patellar tracking is observed arthroscopically to confirm lateral tracking and subluxation. Normally, the patella should be centralized in the trochlear groove at 30° of flexion. After the arthroscope is removed, Mayo scissors are introduced through the portal and a plane is bluntly dissected between the subcutaneous tissue and the extensor retinaculum. The scissors are then inserted into the knee joint for localization of the retinaculum, capsule, and synovium between its blades. These structures are then divided at an angle of 30° posterior to the

long axis of the femur. Care is taken to extend the release up to the vastus lateralis insertion into the rectus femoris. The arthroscope is then reinserted and the release inspected. Any remaining tight bands are then released using scissors or basket forceps, and it is confirmed that the release was performed superiorly enough so that vastus lateralis muscle fibers are now visualized. Patellar tracking is again observed after release to ensure that centralization has been attained. The portal is closed using a single nylon suture and a compression dressing is applied. Lateral compression is then applied using a Velcro lateral release brace before deflation of the tourniquet. Three-point partial weight-bearing begins immediately postoperatively. Isometric quadriceps exercises begin on postoperative day 1, and at 48 hours, active assisted range of motion of the knee has begun. When a painless arc of 90° is achieved, active resisted range of motion is started. The compression brace is worn consistently for 2 weeks, at which time static quadriceps and hamstring exercises are begun and swimming is encouraged. These exercises are continued for at least 3 months postoperatively.

In a study involving 34 knee injuries, 65% had good or excellent results with the above protocol. There were four poor results. Two required re-release arthroscopically, one required an open lateral release, and one required an arthroscopic patellar shaving. One knee in 34 required an aspiration on two occasions for a persistent hemarthrosis and ended up with a good postoperative result.<sup>30</sup>

### Open Lateral Patellar Retinacular Release

An arthroscopic lateral retinacular release has the advantages of smaller incisions, decreased hospitalization and rehabilitation period, and less scar-tissue formation. Excellent visualization is obtained and a thorough examination of the rest of the knee may be performed. If one is not thoroughly familiar and comfortable with arthroscopic techniques, then an open lateral patellar retinacular release may be performed for the skeletally immature individual as well.

A lateral 5- to 6-cm incision is made from Gerdy's tubercle to the junction of the quadriceps fascia with the iliotibial band at the level of the proximal lateral femoral condyle. Care is taken not to open the knee's fat pad capsule. A Cobb elevator is used to separate the lateral retinaculum from the skin and vastus lateralis. A longitudinal incision is then made in the lateral retinaculum, dividing its fibers from the extensor mechanism. Approximately one third of the width of the retinaculum is left attached to the extensor mechanism. Longitudinal division of the lateral retinaculum is carried proximally for a distance of 8 to 10 cm using a meniscomote. Lateral pressure is placed on the patella to show any outstanding lateral fibers that cause tethering. During this procedure, the lateral geniculate artery is identified and cauterized. Next, the synovium is opened and the joint inspected. The femoral condyles are visualized and palpated, and the patella is everted and inspected. At the end of the procedure, the knee is moved from flexion to extension. A gap of between 1.5 and 2.5 cm between

the cut edges of the lateral retinaculum is considered adequate. The tourniquet is released and hemostasis is deemed vital. A compression dressing with a lateral release brace is applied.

In one of our follow-up studies, 77% of 30 knees undergoing an open lateral release showed good or excellent results. One patient with a poor result developed reflex sympathetic dystrophy and had persistent patellar pain and subluxation.<sup>31</sup>

### Green Quadricepsplasty

For the majority of patients who require operative intervention, the arthroscopic lateral release will be the first line of choice. Because this may be between 65% and 85% successful, other options must be available within a surgeon's expertise to combat recalcitrant problems. For the skeletally immature patient with open physes, distal osseous realignment procedures are prohibited. Procedures such as the Elmslie-Trillat, the Maquet, or the Fulkerson realignment involve bony transfers and would thereby disturb the growth plate of the proximal tibia. In the past, the choice of proximal patellar realignment in our clinic was the Green quadricepsplasty. This extensive repositioning of the extensor mechanism is still sometimes required in cases of congenital dislocation of the patella or in Down's syndrome with a fixed dislocation. Its technique is included for completeness.

The Green quadricepsplasty is begun by making two incisions: one exposes the medial aspect of the quadriceps mechanism beginning at the medial tibial plateau and working proximally, and the other incision is lateral, beginning at the lateral jointline and working proximally. Skin flaps are developed and the quadriceps muscle, the patella, patellar tendon, patellar retinaculum, joint capsule, and iliotibial band are exposed. Starting laterally at 1.5 in superior to the femoral condyle, a 3-in segment of the fascia lata and the lateral intermuscular septum are excised (Fig 4A). The contracted iliotibial tract, patellar retinaculum, and lateral joint capsule are then longitudinally divided in their posterolateral portions so as to allow free and medial displacement of the patella (Fig 4B). The perforating arteries that are encountered are ligated. The vastus medialis muscle and periosteum of the superior and medial border of the patella are then detached by a U-shaped incision (Fig 4C). The patella is then medially displaced and the capsule and medial retinaculum are imbricated and closed with reefing sutures (Fig 4D). This is performed with the knee in complete extension. The now-freed vastus medialis tendon is transferred laterally and distally (deep to the patellar bursa) and is sutured to the roughened anterolateral surface of the patella and the patellar tendon (Fig 4E). After layered closure, the knee is placed in a long leg cylinder cast in neutral position. The patient is allowed three-point partial weight bearing and will begin early isometric quadriceps exercises. After 3 to 4 weeks, the cast is removed and the patient is placed in a lateral release brace for the next 4 weeks. Knee motion and strength are gradually increased.<sup>32</sup>

In a follow-up of 31 knee injuries at a mean time of 14 years, 64% of the patients were found to have good or

excellent results. Earlier operative intervention was recommended because of a significantly better outcome in patients who had not yet developed chondromalacia. In this series, results in females were significantly better than males.<sup>33</sup>

### Lateral Release With Medial Plication

In cases of persistent lateral displacement of the patella in the trochlear groove, with or without trochlear dysplasia, we have been accustomed to doing a short, longitudinal median parapatellar incision and plicating the medial retinaculum of the patellar mechanism. We have had good results by leaving the medial retinaculum of the vastus medialis and obliquus intact and directing a series of mattress sutures, beginning at the patella and proceeding from proximal to distal, in such a fashion as to plicate the end more distally and transfer and direct the quadriceps muscle pull. These mattress sutures can be left in place with simple snaps holding them and can be mechanically tightened while the patellar tracking is observed arthroscopically. If tracking is satisfactory, they may be tied down tightly into place, taking up the redundancy of the medial tissue.

In certain acute patellar dislocations, where there is persistent displacement and where arthroscopic evaluation has been required because of chondral or osteochondral injury, we have often proceeded to a lateral release with medial plication. This same technique of a short median parapatellar incision can be used, but the operator must be aware of the fact that in some of the dislocations the injury to the medial retinaculum may have occurred more proximally at the medial intermuscular septum and the plication repair may have to be carried up into this area for complete realignment and tightening of the medial retinaculum. The site of the medial retinacular injury can be determined by careful palpation and determination of sites of maximum tenderness prior to surgery or, in certain cases, by magnetic resonance imaging.

### Galleazzi Semitendinosus Tenodesis

The Galleazzi semitendinosus tenodesis is an alternative method for treatment of the recalcitrant patient with significant patellar malalignment in which both proximal and distal realignment is necessary. This is performed in a patient with open physes, significant distal patellofemoral malalignment, and patellotrochlear hypoplasia in association with generalized ligamentous laxity.<sup>25</sup>

As initially described, an oblique medial parapatellar incision was used to harvest the semitendinosus tendon and to perform open release of the lateral structures. In recent years, with the availability of arthroscopy, a short medial incision is used to harvest the semitendinosus tendon; lateral release is done with arthroscopic control; and a short lateral parapatellar incision is used to secure the semitendinosus after it is passed across the patella. The semitendinosus tendon is identified through a median parapatellar incision. Care is taken to not injure the posterior femoral cutaneous nerve (lying laterally to the semitendinosus and medially to the biceps

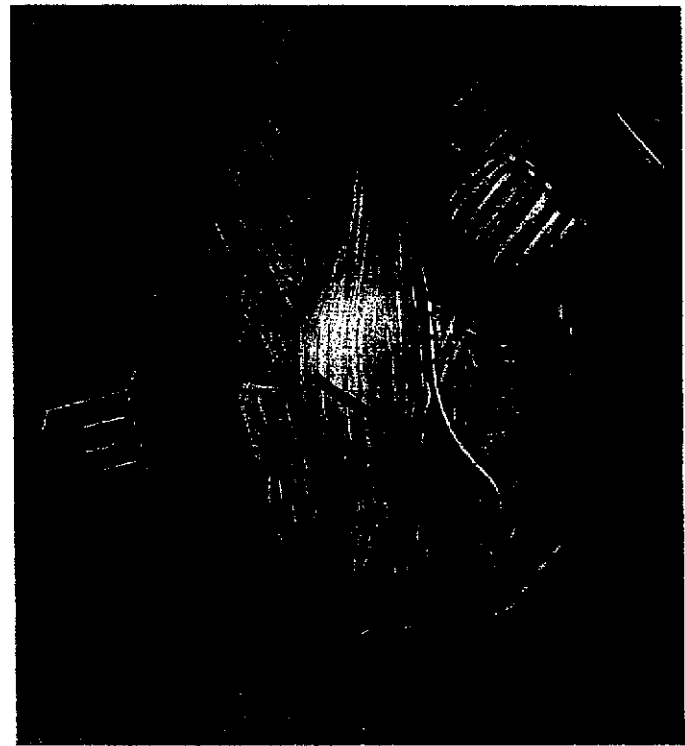
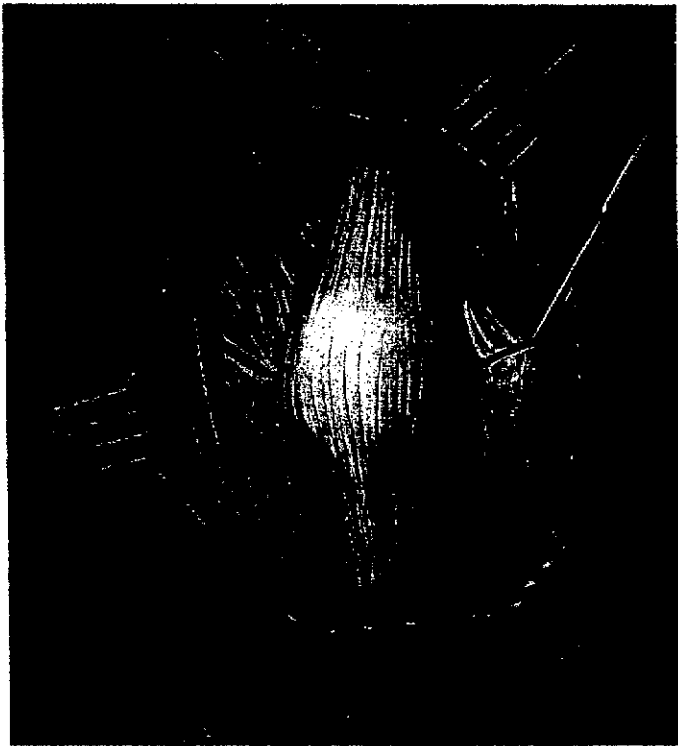
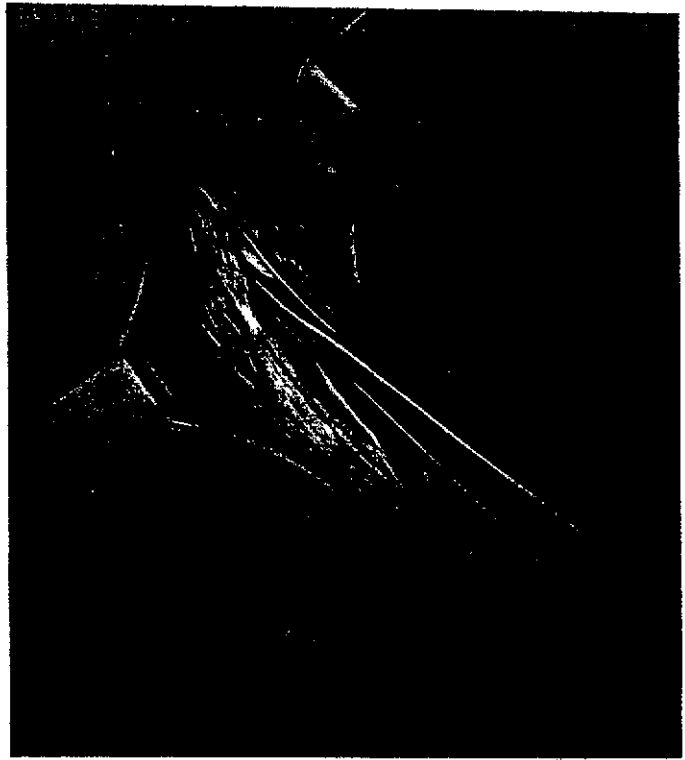
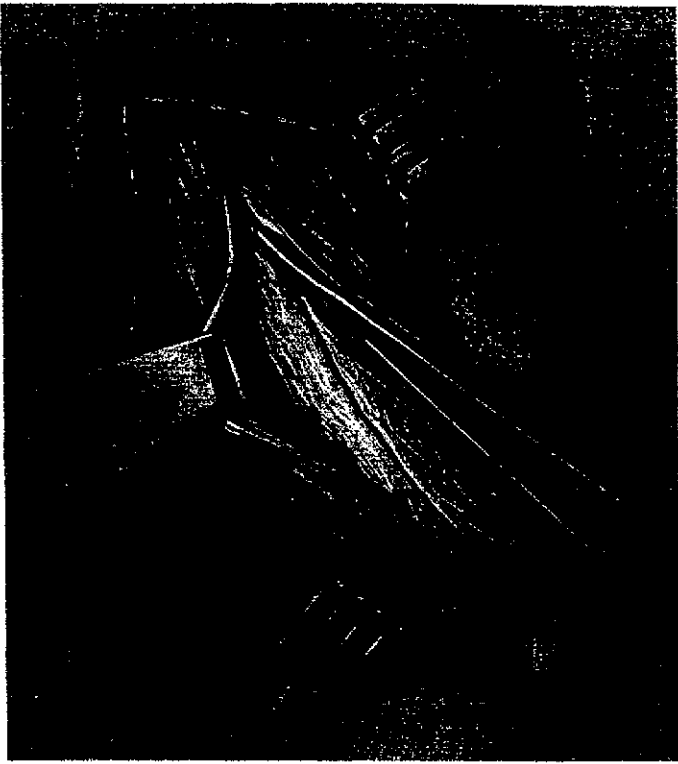


Fig 4. The Green quadricepsplasty (see text for explanation).<sup>32</sup> Continued on following page.

tendon) when harvesting this tendon. This tendon is detached at its musculotendinous junction and left attached distally. The infrapatellar branch of the saphenous nerve is at risk near the distal attachment of this tendon. A lateral skin flap is developed so that the anterior surface of the patella and extensor mechanism is exposed. An arthroscopic lateral release is then performed. The intent of this procedure is to redirect the

pull of the extensor mechanism so that it lines up with the intercondylar notch of the femur (Fig 5, A and B). This is done by drilling an oblique hole across the patella in the line of the proposed tenodesis from inferomedially to superolaterally. The tendon is then passed from the medial to the lateral side. Appropriate tension is placed on the tendon so as to pull the patella distally and medially and it is held there while the tendon is sewn back on



Fig 4. (cont'd).

itself. This procedure is combined with a medial capsular and retinacular plication as necessary. The vastus lateralis may be released and the vastus medialis, advanced distally and laterally, is attached to the anterior of the now tensioned semitendinosus tendon. This thereby corrects the oblique course of the vastus medialis to a more transverse one. If the medial direction of the semitendinosus distally results in excessive redundancy of the patellar tendon, a Roux-Goldthwaite redirection of the tendon may be added. This entails splitting the pa-

tellar tendon in half, detaching the lateral half, and directing this half under the medial half. It is then attached to the periosteum of the tibia under appropriate tension.<sup>34-36</sup>

In a series of 26 knee injuries with an average follow-up of 43 months, 62% were reported to have good/excellent results. The other 38% had persistent pain caused by chondromalacia noted at the time of surgery. The duration of preoperative symptoms and the condition of the cartilage at the time of surgery are the major prognostic indicators of the functional end result. An additional Roux-Goldthwaite procedure was performed in 73% of these patients. Although the Galleazzi semitendinosus tenodesis may not provide complete correction in the patient with ligamentous laxity, it may serve to preserve growth plates and articular cartilage until such time as distal bony realignment is possible.<sup>36</sup>

## CONCLUSION

Many disorders involving the patellofemoral joint may cause significant disability in the skeletally immature population. One must take great care in making an accurate diagnosis. Because there are many variants in the presentation of these problems, a thorough understanding of the anatomy and pathomechanics is essential for the treating physician. These patients may still have a significant amount of growth remaining; therefore, caution is mandatory when deciding on the proper treatment. Initially, it is usually prudent to treat these patients conservatively with encouragement, goal-directed rehabilitation, and serial examinations. This affords the physician an opportunity to observe the progression and motivation of the patient as well as to confirm the presumed diagnosis. If this fails, operative measures may be considered while always keeping in mind the potential risk to the growing physes. Following these guidelines will help to avoid problems and pitfalls and will lead to a



Fig 5. Galleazzi semitendinosus tenodesis. (A) Semitendinosus tendon passed through the patella after lateral release. (B) Tendon sutured under tension drawing the patella medial and downward.<sup>37</sup>

successful treatment for patellofemoral disorders in the skeletally immature patient.

## REFERENCES

1. Kempe C, Silver H, O'Brien D (eds): Current Pediatric Diagnosis and Treatment. Los Angeles, CA, Lange Medical Publications, 1984
2. Micheli LJ: Overuse injuries in children's sports: the growth factor. *Orthop Clin North Am* 14:337-360, 1983
3. Stanisavljevic S, Semenick G, Miller D: Congenital, irreducible, permanent lateral dislocation of the patella. *Clin Orthop* 116:190-199, 1976
4. McCall RE, Lessenberry HB: Bilateral congenital dislocation of the patella. *J Pediatr Orthop* 7:100-102, 1987
5. Dahners LE, Francisco WD, Halleran WJ: Findings at arthroscopy in a case of double layered patellae associated with multiple epiphyseal dysplasia. *J Pediatr Orthop* 2:67-70, 1982
6. Gasco Del Pino JM, Gomar-Sancho F: Double patella: A case of duplication in the coronal plane. *J Bone Joint Surg [Br]* 69:602-603, 1987
7. Mansoor IA: Dysplasia epiphysealis multiplex. *Clin Orthop* 72:287-292, 1970
8. Duthie RB, Hect F: The inheritance and development of the nail-patella syndrome. *J Bone Joint Surg [Br]* 45:259-267, 1963
9. Mendez AA, Keret D, MacEwen GD: Treatment of patellofemoral instability in Down's syndrome. *Clin Orthop* 234:148, 1988
10. Merchant AC: Classification of patellofemoral disorders. *Arthroscopy*, 4:235, 1988
11. Merchant AC: Extensor mechanism injuries: Classification and diagnosis, in Scott WN (ed): Ligament and Extensor Mechanism Injuries of the Knee. Diagnosis and Treatment. St Louis, MO, Mosby, 1991, p 174
12. McManus F, Rang M, Heslin DJ: Acute dislocation of the patella in children: the natural history. *Clin Orthop* 139:88-91, 1979
13. Donelson RC, Tomaiuolo M: Intra-articular dislocation of the patella: A case report. *J Bone Joint Surg [Am]* 61:615-616, 1979
14. Ogden JA: Skeletal Injury in the Child. Philadelphia, PA, Saunders, 1990, p 752
15. Ficat RP, Hungerford DS: Disorders of the Patellofemoral Joint. Baltimore, MD, Williams & Wilkins, 1977
16. Radin EL, Paul IL: Response of joints to impact loading. I. In vitro wear. *Arthritis Rheumatol* 14:356-362, 1971
17. Zimmerman NB, Smith DG, Pottenger LA, et al: Mechanical disruption of human patellar cartilage by repetitive loading in vitro. *Clin Orthop* 229:302-307, 1988
18. Repo RU, Finlay JB: Survival of articular cartilage after controlled impact. *J Bone Joint Surg [Am]* 59:1068-1076, 1977
19. Mankin HJ: The response of articular cartilage to mechanical injury. *J Bone Joint Surg [Am]* 64:460-466, 1982
20. Ohno O, Naito J, Iguchi T, et al: An electron microscopic study of early pathology in chondromalacia of the patella. *J Bone Joint Surg [Am]* 70:883-899, 1988
21. Karlson S: Chondromalacia patellae. *Acta Chir Scand* 83:347-381, 1939
22. Goodfellow J, Hungerford G, Zindel M: Patello-femoral mechanics and pathology. 1. Functional anatomy of the patello-femoral joint. *J Bone Joint Surg [Br]* 58:287-290, 1976
23. Bentley G: Chondromalacia patellae. *J Bone Joint Surg [Am]* 52:221-232, 1970
24. Maquet P: Mechanics and osteoarthritis of the patellofemoral joint. *Clin Orthop* 144:70-73, 1979
25. Thabit G III, Micheli LJ: Patellofemoral pain in the pediatric patient. *Orthop Clin North Am* 23:567-585, 1992
26. Micheli LJ: Special considerations in children's rehabilitation programs, in Hunter LY, Funk FJ Jr (eds): Rehabilitation of the Injured Knee. St Louis, MO, Mosby, 1984, pp 406-413
27. O'Neill DB, Micheli LJ, Warner JP: Patellofemoral stress: A prospective analysis of exercise treatment in adolescents and adults. *Am J Sports Med* 20:151-156, 1992
28. DeHaven KE, Dolan WA, Mayer PJ: Chondromalacia patellae in athletes: Clinical presentation and conservative management. *Am J Sports Med* 7:5-11, 1979
29. Henry JH: Conservative treatment of patellofemoral subluxation. *Clin Sports Med* 8:261-278, 1989
30. Lankenar PA Jr, Micheli LJ, Clancy R: Arthroscopic percutaneous lateral-patellar retinacular release. *Am J Sports Med* 14:267-269, 1986
31. Micheli LJ, Stanitski CL: Lateral patellar retinacular release. *Am J Sports Med* 9:330-336, 1981
32. Tachdjian MO: Pediatric Orthopaedics. Philadelphia, PA, Saunders, 1972, pp 732-739
33. Laurencin CT, Silver SA, Tannenbaum D, Micheli LJ: Late results of the Green quadricepsplasty for recurrent dislocation of the patella. *Clin J Sport Med* 2:244-246, 1992
34. Hall JE, Micheli LJ, McManama GB Jr: Semitendinosus tenodesis for recurrent subluxation or dislocation of the patella. *Clin Orthop* 144:31-35, 1979
35. Goldthwaite JE: Slipping or recurrent dislocation of the patella with a report of eleven cases. *Boston Med Surg J* 150:169-173, 1904
36. Rask BP, Micheli LJ: The pediatric knee. In Scott WN (ed): The Knee, vol 1. St Louis, MO, Mosby-Year Book, 1994, pp 229-275
37. Baker RH, Carroll N, Dewar FB, et al: The semitendinosus tenodesis for recurrent dislocation of the patella. *J Bone Joint Surg [Br]* 54:103-109, 1972