

# Isolated Medial Collateral Ligament Injuries in the Knee

Peter A. Indelicato, MD

## Abstract

The management of ligament injuries in the knee has progressed significantly over the past two decades as a result of both laboratory and clinical studies that better define the healing capacity of these supporting structures. The intracapsular ligaments (the anterior and posterior cruciate ligaments) appear to have limited potential for spontaneous healing and frequently require surgical reconstruction. The extracapsular ligaments (the medial and lateral collateral ligaments), however, appear to have a fairly robust potential for healing. As a result, the need for surgical intervention is limited to specific clinical situations.

J Am Acad Orthop Surg 1995;3:9-14

The management of ligament injuries to the knee continues to evolve. Better understanding of the biomechanical function and physiologic healing process of these important structures affords the clinician a greater opportunity to secure a successful outcome when major damage to the cruciate and collateral ligaments of the knee is encountered.

In this article I will review the anatomy, clinical examination, and management of isolated complete medial collateral ligament (MCL) tears in the knee.

## Functional and Surgical Anatomy

The nomenclature describing the medial ligamentous structures of the knee has been somewhat confusing. In the past, the MCL has been called the "superficial medial collateral ligament" or the "tibial collateral ligament."

The MCL is attached proximally to the medial femoral condyle and distally to the metaphyseal area of the tibia, 4 or 5 cm distal to the medial joint line beneath the pes anserinus

insertion. Immediately deep to the MCL is the medial capsular ligament. Posterior to the MCL is a thickening of the capsular ligament specifically referred to as the posterior oblique ligament (Fig. 1, A).

The main medial stabilizer that resists valgus loading is the MCL.<sup>1,2</sup> Grood et al<sup>1</sup> have shown that the MCL contributes 78% to the restraining force on the medial side of the knee. Because of its parallel collagen arrangement, only 5 to 8 mm of increased opening indicates a complete failure of the ligament. Even though this difference in laxity between the injured knee and the uninjured knee is small, significant damage has occurred to the primary restraint on the medial side of the knee, a fact not stressed enough when teaching physical examination of the knee. The midmedial portion of the medial capsular ligament, deep to the MCL, provides a firm attachment site for the medial meniscus, but does not provide significant restraint against direct valgus stress.

Müller<sup>3</sup> refers to the posteromedial aspect of the knee (posterior

oblique ligament) as the "semimembranosus corner." According to him, the semimembranosus muscle, through its various attachment sites, "dynamizes" this area of the knee during active contracture and provides support even with the knee in flexion. In addition, he states that surgical repair of damage to this area is essential to eliminate any valgus laxity that exists with the knee in full extension. Finally, he points out the anatomic connection between the vastus medialis muscle and the MCL and states that the MCL is also dynamized by contraction of the vastus medialis during active extension (Fig. 1, B).

Grood et al,<sup>1</sup> Warren et al,<sup>2</sup> and Müller<sup>3</sup> have pointed out the contribution of the MCL and the posterior oblique ligament in resisting abnormal external tibial rotation. However, the degree of external rotation that results from sectioning these two ligaments appears to be minimal and should not be confused with the more anteromedial rotatory instability that occurs with combined failure of the MCL and the anterior cruciate ligament (ACL).

---

*Dr. Indelicato is Professor of Orthopaedics and Huizenga Professor of Sports Medicine, University of Florida, Gainesville.*

*Reprint requests: Dr. Indelicato, University of Florida Sports Medicine Center, 200 SW 62nd Boulevard, Suite B, Gainesville, FL 32607.*

*Copyright 1995 by the American Academy of Orthopaedic Surgeons.*

---

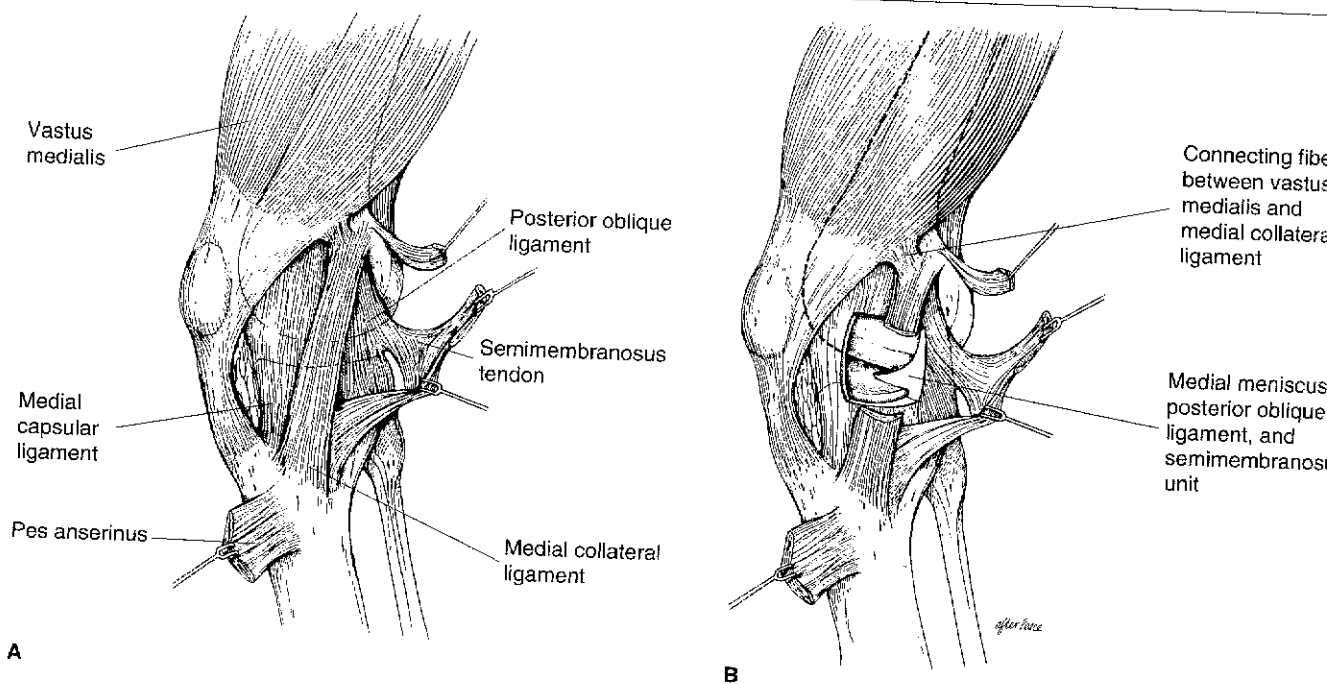


Fig. 1 A, The medial capsuloligamentous complex. B, According to Müller,<sup>3</sup> the MCL is dynamized by the connecting fibers of the vastus medialis, and the posterior oblique ligament is dynamized by the semimembranosus.

It is critical to understand the surgical anatomy in order to appreciate the relationship the various important stabilizing structures have with the MCL. Warren and Marshall<sup>4</sup> have defined three distinct layers, each containing important structures and landmarks. The most superficial layer (layer I) consists of the deep fascia encompassing the patellar tendon anteriorly and the popliteal fossa posteriorly and enveloping the medial hamstrings. Layer II is mainly composed of the MCL, which blends posteriorly with layer III, the posteromedial capsule (posterior oblique ligament). Layer III consists of the medial capsular ligament and blends posteriorly with layer II to form the posterior oblique ligament. There is a bursa that separates layer II, containing the MCL, from the medial capsular ligament immediately beneath it. According to Müller, this bursa

allows the MCL to glide for the required 1.5-cm anteroposterior excursion during flexion/extension of the knee.<sup>3</sup> This bursa can be used as a familiar landmark for proper orientation when surgical repair is required.

### Clinical Examination

A critical part of the history is to determine the mechanism of a potential MCL injury in the knee. The vast majority of significant MCL injuries involve a valgus force applied laterally to the lower thigh or upper leg. Although complete tears can occur from a rotational force alone, such as occurs in snow skiing, significant tears are more likely in contact sports, such as football and rugby. Since most forces are coupled (i.e., valgus and external rotation), it is not unusual to find

combined damage to both the MCL and the posterior oblique ligament. Müller stated that a pure valgus force to the lateral aspect of the knee without any rotational component will mainly damage the MCL.<sup>3</sup> If, however, a combination of valgus and external rotational force is sustained, tears primarily to the posterior oblique ligament and possibly to the ACL can occur before the MCL is significantly damaged.

When performing the physical examination, it is critical to keep in mind some basic principles. The patient must be relaxed and the contralateral knee must be used as a control to determine the presence and degree of asymmetrical medial joint opening. The key element of the physical examination is the application of a gentle valgus force with the patient's knee in slight flexion (30 degrees). When examining a large patient, one should let the thigh rest

on the table and drop the lower leg off to the side while supporting the foot and ankle (Fig. 2). This gives the patient the opportunity to relax and keep the thigh musculature flaccid, a prerequisite for an accurate assessment in the presence of abnormal ligamentous laxity. For a brief period of time following the injury, a patient may be relatively pain-free even if the MCL is completely torn. Such a situation provides a golden opportunity to perform a very thorough and reliable physical examination. The degree of medial joint opening relative to the uninjured knee is a direct measure of damage to the MCL. It is worth emphasizing that a difference of only 5 to 8 mm is indicative of significant structural damage to the MCL.<sup>1</sup>

The second part of the examination, which evaluates the extent of medial soft-tissue damage, is performed with the knee in full extension. The valgus force is repeated,



Fig. 2 Placing the injured leg over the side of the table will help the patient relax while allowing the knee to flex the necessary 30 degrees.

and once again the degree of medial joint opening is compared with that in the uninjured knee. Asymmetrical opening in full extension is indicative of combined MCL and posterior oblique ligament damage and should alert the examiner to the possibility of an associated ACL or posterior cruciate ligament injury. Thus, gross medial opening in full extension strongly indicates damage to the cruciate ligaments. If the knee is stable in full extension, one can safely assume that there is no significant damage to the posterior oblique ligament.

A more subtle examiner skill is the evaluation of the "quality of the end point." When a complete MCL tear is present, no firm end point is encountered. In isolated complete tears of the MCL, the end point in the valgus stressed knee in slight flexion is the intact ACL. However, this end point is encountered quite beyond the normal medial opening as determined by comparison to the normal contralateral knee.

Finally, it is important to distinguish between localized soft-tissue swelling and a hemarthrosis. The former is commonly seen in association with MCL damage; the latter is seen more frequently with associated ACL rupture. When combined damage to both the MCL and the ACL is present, the size of the hemarthrosis may be minimal because of the extravasation of blood outside the knee through the tear of the medial capsular ligament.

Although the history and physical examination are critical to determination of the type and degree of ligamentous damage to the knee, it may be difficult to perform the appropriate examination due to pain, swelling, and muscle spasm. In this situation, it is helpful to splint the extremity and reexamine the patient a few days later when the swelling and pain have diminished. If this proves unsuccessful, magnetic resonance (MR) imaging may be

considered to highlight the location and extent of ligamentous damage present, as well as to determine whether there are coexisting meniscal abnormalities. Because of the development of MR imaging, diagnostic arthroscopy in this clinical situation is now used less frequently.

## Management

### Grade I and II Injuries

The extent of ligamentous damage determined on clinical examination dictates treatment. Bergfeld<sup>5</sup> has outlined the management of incomplete tears of the MCL. During the first 48 hours, ice, compression, and elevation should be used as much as possible. In general, incomplete tears of the MCL are treated with temporary immobilization and the use of crutches for pain control. Isometric, isotonic, and eventually isokinetic progressive resistive exercises are begun within a few days of the subsidence of pain and swelling. Weight-bearing is encouraged, the rate being dictated by the level of pain. Occasionally, persistent pain over the posterior oblique ligament prevents full, pain-free extension; in this setting, the recovery can be somewhat prolonged.

Derscheid and Garrick<sup>6</sup> treated 51 incomplete tears of the MCL in a prospective study performed in college football players. A specific rehabilitation protocol, similar to that outlined above, was followed. All players with grade I injuries returned to full, unprotected participation an average of 10.6 days after injury; for players with grade II injuries, the return took 19.5 days. Although a slight amount of residual laxity remained, it proved to be of no functional significance.

### Grade III Injuries

In 1950, O'Donoghue<sup>7</sup> advocated the immediate repair of all complete

tears of the MCL whether they occurred as an isolated injury or in conjunction with other major ligament damage: "The knee which demonstrates a serious or complete rupture of the medial collateral ligament, a fracture of the meniscus, or a tear in the cruciate, or any combination of these, should have early and careful repair not of one or two, but of all damaged structures." In 1983, Hughston and Barrett<sup>8</sup> advocated primary repair of all torn medial structures, including the MCL and the posterior oblique ligament, when complete disruption is discovered on clinical examination. They believed that anterior advancement of the posterior oblique ligament was the key to restoring medial stability and advocated proper tensioning of each suture under direct visualization. Müller<sup>3</sup> performed a primary repair of the MCL using various methods of fixation and reported good or excellent results in 86% of cases.

Other authors have advocated nonoperative intervention when the MCL is completely torn. In 1974, Eilssasser et al<sup>9</sup> observed that severe tears of the MCL in professional football players could be treated nonoperatively with a high degree of success. In 1978, Fetto and Marshall<sup>10</sup> reported equally satisfactory results in isolated complete tears of the MCL, irrespective of whether they were repaired primarily or treated conservatively. However, they stressed the importance of identifying any associated ligamentous damage (particularly to the ACL) and stated that the results were universally poor when combined ligamentous injuries were treated nonoperatively. More recent studies have highlighted the importance of identifying coexisting ACL damage and the deleterious effect it may have on MCL healing.<sup>11-13</sup> For example, in 1988, Kannus<sup>14</sup> reported poor long-term results of nonoperative treat-

ment of complete MCL tears in 27 patients.

Jones et al<sup>15</sup> reported the results of nonoperative treatment of complete isolated MCL tears in 24 high school football players. The players were able to return to competition an average of 34 days after injury even though some had some mild residual medial laxity on physical examination.

A recent study performed by Reider et al<sup>16</sup> supports the concept of early motion and functional rehabilitation in the management of isolated MCL injuries in athletes. The data on 35 patients were reviewed (average follow-up, over 5 years). The overall results were very good. Nineteen of 34 patients estimated their time to full recovery to be under 2 months. Thirty-three patients were able to return to full participation in the preinjury sport. Sixteen of 19 football players returned to the sport within 4 weeks after the injury.

My preferred method for treating isolated complete MCL tears has not changed very much since 1983.<sup>17</sup> Provided structural damage to either cruciate ligament has been excluded by clinical examination or MR imaging, I believe that primary repair of the MCL is not necessary, and a structured program of rehabilitation can provide predictably good results in the vast majority of cases.<sup>18</sup> What has changed over the past few years is the rate of progression of the rehabilitation program. Compared with the original protocol published in 1983, the program has become much more aggressive and driven by patient comfort and performance rather than by any predetermined period of time.

I also believe that arthroscopy is no longer indicated in every case. An accurate clinical examination with particular emphasis on the Lachman test is sufficient to evaluate the extent of damage to the ACL.

During examination of the knee soon after injury, the presence of joint-line tenderness does not necessarily mean a substance tear of the medial meniscus. Occasionally, MR imaging is helpful in determining whether there is any coexisting damage to the meniscus, although it has been my experience that it is unusual to have significant damage to the body of the meniscus when there is a complete disruption of the MCL.

Once it has been established that no structural damage to other ligaments has occurred, a structured supervised program is begun. If the knee is not too painful, a hinged brace is used, and quadriceps-strengthening exercises and straight leg raises are encouraged immediately. If the knee is painful, it is placed in full extension in an immobilizer without hinges. When the initial pain and swelling subside, the patient is instructed to remove the immobilizer five times daily and to perform a range-of-motion program, the limits of motion being dictated by comfort, optimally for 5 minutes each set.

Usually, the patient can easily flex the knee beyond 90 degrees within 10 to 14 days, and the immobilizer can then be removed. When the patient can walk without a noticeable limp, the crutches are discontinued. No form of brace is recommended at this point. Once the knee can be flexed beyond 100 degrees, the use of a stationary bicycle is started. This encourages further motion and builds strength.

It is important to note that it is unusual for an effusion to develop during the rehabilitation program. If a recurrent effusion is noted, particularly more than once, the possibility of undiagnosed associated meniscal and/or articular cartilage damage should be considered.

As stated previously, a small group of patients develop postero-medial pain that prevents comfortable full extension at the beginning of

their rehabilitation program. However, this is much more likely to occur in patients with incomplete tears of the posterior oblique ligament and associated vastus medialis damage than it is in patients with complete tears of the MCL not involving the posterior oblique ligament.

When the patient regains 60% of his quadriceps strength, as determined on isokinetic testing, he is allowed to start a straight-ahead jogging program. Usually this takes place within the first 3 weeks of therapy. Jogging may be started sooner on a trampoline or in a pool in chest-deep water. Usually within a few more weeks the quadriceps and hamstring strength will be 80% of that on the contralateral leg. When this occurs, the patient is provided with a functional orthosis, and an agility program is begun. I prefer an off-the-shelf model, the type usually recommended following ACL surgery. Return to contact sports is permitted whenever the patient can perform an agility program equivalent to that needed to play his sport. I encourage the use of a functional brace for the remainder of the season because players feel that such bracing provides additional protection. However, continued use of the brace is discouraged when the player returns the following season. Because prophylactic knee bracing remains controversial, routine use is not encouraged.

The obvious question arises: "When, if ever, should primary repair of a complete MCL tear be performed?" There still remains some controversy over this issue. Recently, Shelbourne and Porter<sup>19</sup> reported the results in 68 patients who had tears of both the MCL and the ACL. The ACL tear was treated with a primary reconstruction using autogenous patellar tendon, and the MCL tear was managed nonoperatively. They concluded that good to excellent results could be achieved without primary repair of the MCL rupture and saw no advantage to the additional surgery.

My approach to combined ACL-MCL damage is to decide intraoperatively whether the MCL rupture requires primary repair. After the ACL reconstruction is complete, the medial laxity is reassessed. If the knee continues to be unstable in full extension or slight flexion (grade II or III), the MCL and the posterior oblique ligament are exposed, and a primary repair is performed. Unlike Hughston and Barrett,<sup>8</sup> however, I avoid reefing or advancement of the posterior oblique ligament during the repair in order to avoid the risk of a flexion contracture. If the degree of medial laxity has been reduced to grade I after the ACL reconstruction, primary repair of the medial ligament damage is not necessary. Regardless of whether a primary medial repair has been performed,

the knee is placed in full extension, and a range-of-motion program is started early. The rehabilitation program is focused mainly on the ACL rather than the MCL.

### Summary

Clinical evaluation of patients with complete tears of the MCL will dictate the course of action necessary for a successful outcome. When associated damage to the ACL can be ruled out, primary repair is usually not necessary. Although it is important to document the mechanism of injury, the correct diagnosis is dependent on the results of the physical examination. Magnetic resonance imaging and diagnostic arthroscopy should be reserved for those situations in which the extent of damage remains questionable. There is little controversy regarding the management of incomplete tears of the MCL and the posterior oblique ligament. Although in the past some authors recommended primary repair for all complete tears of the MCL, the pendulum appears to have swung toward nonoperative management of these lesions in most cases. There still remains some controversy regarding the management of these tears when they are discovered in conjunction with tears of either cruciate ligament.

### References

1. Grood ES, Noyes FR, Butler DL, et al: Ligamentous and capsular restraints preventing straight medial and lateral laxity in intact human cadaver knees. *J Bone Joint Surg Am* 1981;63:1257-1269.
2. Warren LF, Marshall JL, Girgis F: The prime static stabilizer of the medial side of the knee. *J Bone Joint Surg Am* 1974;56:665-674.
3. Müller W: *The Knee: Form, Function, and Ligament Reconstruction*. New York: Springer-Verlag, 1983.
4. Warren LF, Marshall JL: The supporting structures and layers on the medial side of the knee: An anatomical analysis. *J Bone Joint Surg Am* 1979;61:56-62.
5. Bergfeld J: First-, second-, and third-degree sprains. *Am J Sports Med* 1979;7: 207-209.
6. Derscheid GL, Garrick JC: Medial collateral ligament injuries in football: Nonoperative management of grade I and grade II sprains. *Am J Sports Med* 1981;9:365-368.
7. O'Donoghue DH: Surgical treatment of fresh injuries to the major ligaments of the knee. *J Bone Joint Surg Am* 1950;32:721-738.
8. Hughston JC, Barrett GR: Acute antero-medial rotatory instability: Long-term

## Medial Collateral Ligament Injuries

- results of surgical repair. *J Bone Joint Surg Am* 1983;65:145-153.
9. Ellsasser JC, Reynolds FC, Omohundro JR: The non-operative treatment of collateral ligament injuries of the knee in professional football players: An analysis of seventy-four injuries treated non-operatively and twenty-four injuries treated surgically. *J Bone Joint Surg Am* 1974;56:1185-1190.
  10. Fetto JF, Marshall JL: Medial collateral ligament injuries of the knee: A rationale for treatment. *Clin Orthop* 1978;132:206-218.
  11. Anderson DR, Weiss JA, Takai S, et al: Healing of the medial collateral ligament following a triad injury: A biomechanical and histological study of the knee in rabbits. *J Orthop Res* 1992;10:485-495.
  12. Inoue M, McGurk-Burleson E, Hollis JM, et al: Treatment of the medial collateral ligament injury: I. The importance of anterior cruciate ligament on the varus-valgus knee laxity. *Am J Sports Med* 1987;15:15-21.
  13. Woo SLY, Inoue M, McGurk-Burleson E, et al: Treatment of the medial collateral ligament injury: II. Structure and function of canine knees in response to differing treatment regimens. *Am J Sports Med* 1987;15:22-29.
  14. Kannus P: Long-term results of conservatively treated medial collateral ligament injuries of the knee joint. *Clin Orthop* 1988;226:103-112.
  15. Jones RE, Henley MB, Francis P: Non-operative management of isolated grade III collateral ligament injury in high school football players. *Clin Orthop* 1986;213:137-140.
  16. Reider B, Sathy MR, Talkington J, et al: Treatment of isolated medial collateral ligament injuries in athletes with early functional rehabilitation: A five-year follow-up study. *Am J Sports Med* 1993;22:470-477.
  17. Indelicato PA: Non-operative treatment of complete tears of the medial collateral ligament of the knee. *J Bone Joint Surg Am* 1983;65:323-329.
  18. Indelicato PA, Hermansdorfer J, Huegel M: Nonoperative management of complete tears of the medial collateral ligament of the knee in intercollegiate football players. *Clin Orthop* 1990;256:174-177.
  19. Shelbourne KD, Porter DA: Anterior cruciate ligament-medial collateral ligament injury: Nonoperative management of medial collateral ligament tears with anterior cruciate ligament reconstruction: A preliminary report. *Am J Sports Med* 1992;20:283-286.