

Gordian Stutz
Markus S. Kuster
Frank Kleinstück
André Gächter

Arthroscopic management of septic arthritis: stages of infection and results

Received: 28 January 2000
Accepted: 2 June 2000
Published online: 20 July 2000
© Springer-Verlag 2000

Abstract Seventy-six patients with septic arthritis (78 affected joints) were treated with a combination of arthroscopic irrigation, débridement, and antibiotic therapy according to the tested bacterial sensitivity. There were 62 knee, 10 shoulder, 5 ankle joints, and 1 hip joint. No antibiotics were added to the irrigating solution. The arthroscopic and radiological stage of infection, treatment, and outcome in these patients was analyzed. The patients were classified into three groups according to initial stage of joint infection (stage I: 21 patients, 22 joints; stage II: 43 patients, 44 joints; stage III: 12 patients, 12 joints). Causes of infection were: hematogenous dissemination in 54%, postoperative wound infection in 28% (17% after open, 11% after arthroscopic procedures). Other causes were: 10% intra-articular steroid injections, 3% diagnostic punctures, and 3% open traumatic injury of the joint. In 78% of the infected joints the causative organism could be identified: *Staphylococcus aureus* was the most common organism found (42%), followed by strep-

tococci (15%), pneumococci (6%), *Escherichia coli* (4%), *Staphylococcus epidermidis* (3%), *Borrelia burgdorferi* (3%), and others in 5%. In the stage I group only one patient needed repeated arthroscopic irrigation, in the stage II group 52%, and in the stage III group 75%. Open revision for eradication of the infection was necessary in one joint with stage II and in two joints with stage III infection (3%). Two joints of the stage III group needed additional surgery after successful treatment of the infection. The combination of arthroscopic irrigation and systemic antibiotic therapy was able to cure 91% of the affected joints. Open revision was necessary in 4% of joints. The number of arthroscopic procedures and the efficacy of treatment depended on the initial stage of the infection. It is concluded that an arthroscopic staging of the initial joint infection has prognostic and therapeutic consequences.

Keywords Arthroscopy · Infection · Risk factors

G. Stutz (✉) · M. S. Kuster · F. Kleinstück
A. Gächter
Department of Orthopedic Surgery,
Kantonsspital St. Gallen,
9007 St. Gallen, Switzerland
e-mail: gordianstutz@yahoo.com
Tel.: +41-71-4941111
Fax: +41-71-4942871

Introduction

The rate of complications and fatal outcomes in the management of septic arthritis was dramatically reduced with the introduction of arthroscopic débridement and the concomitant development of potent antibiotics [37]. The role

of continuous irrigation and the use of antibiotic or anti-septic additives are controversial in the literature. Jackson [18] and Jackson and Parsons [19] have proposed a distension-irrigation technique in which one first irrigates and débrides the joint, then inserts two drains into the joint and distends it through the drains with saline solution with antibiotic and mucolytic agents added over 3 h,

and finally drains the joint for another 1 h. This therapy is continued for 6-8 days. In addition to the local distension/irrigation process, intravenous antibiotics are also administered. Other authors recommend [9, 27] or reject [17, 35] the use of continuous irrigation-suction drains with antibiotics added to the irrigating solution. However, the severity of septic arthritis may vary significantly and could explain some of these controversies. No data have yet been reported on the treatment of septic arthritis in correlation with arthroscopic staging of the infection.

This study presents the results of a management regimen of septic arthritis based on the initial stage of the infection.

Patients and methods

Seventy-six patients (44 men, 32 women) with septic arthritis (78 affected joints) were treated with a combination of arthroscopic irrigation and systemic antibiotic therapy between January 1988 and June 1998 (62 knees, 10 shoulders, 5 ankle and 1 hip joint; Table 1). Patients with total joint replacement were not included in this series. Ringer's solution was used to irrigate the joints, and no antibiotics or antiseptics were added. An average of 5-6 l (2-12 l) were used for irrigation. All wound drains were removed within the first 24 h. During arthroscopy aspirates and biopsy specimens were taken for Gram stain, bacteriological culture, and antibiotic sensitivity tests. Patients with negative microbiology results were included in this series only if the joint fluid examination was negative concerning crystals. Antibiotic therapy was started afterwards. The antibiotic therapy was adapted by the consultant for infectious diseases depending on the final result of the microbiology. In patients with negative bacteriology results intravenous administration of cephalosporine was continued until the C-reactive protein level and erythrocyte sedimentation rate returned to normal. The infection was staged according to the criteria of Gächter [10]:

- Stage I: opacity of fluid, redness of the synovial membrane, possible petechial bleeding, no radiological alterations
- Stage II: severe inflammation, fibrinous deposition, pus, no radiological alterations
- Stage III: thickening of the synovial membrane, compartment formation ("sponge-like" arthroscopic view, especially in the suprapatellar pouch), no radiological alterations
- Stage IV: aggressive pannus with infiltration of the cartilage, possibly undermining the cartilage, radiological signs of subchondral osteolysis, possible osseous erosions and cysts.

Arthroscopic irrigation has been shown to be insufficient in stage IV [11, 12], and open revision was performed; hence patients with stage IV infection were not included in this study.

At the initial arthroscopy 21 patients (22 joints) showed a stage I infection; 43 patients (44 joints) a stage II infection, and 12 pa-

tients (12 joints) a stage III infection. The correlation of results and complications to the initial stage of infection was analyzed retrospectively. If the infection did not recur, and the patient had no further therapy 1 year postoperatively, the infection was considered to be cured.

The average age of the patients was 53 years (range 17-94), in the stage I group 50 years (22-86), in the stage II group 52 years (17-89), and in the stage III group 65 years (range 38-94 years).

Results

A hematogenous cause was found in 54% of the affected joints and a postoperative infection in 28% (17% after open, 11% after arthroscopic procedure). Ten percent of the patients had an intra-articular infiltration of steroids, and 4% had a diagnostic puncture. In 4% there was a traumatic penetration of the joint (Table 2). In 78% of joints the causative organism was identified by bacteriological cultures (Table 3). Almost 25% of those in the stage I and II groups had Gram-negative stains; the causative organism was identified in all but one patient of the stage III group. The most common risk factors for joint infection were generalized sepsis (12%) and trauma (11%).

In stage I, a single arthroscopic irrigation combined with systemic antibiotic therapy was sufficient in 21 of 22 infected joints. One joint underwent a second arthroscopic irrigation. The septic arthritis was cured by arthroscopic therapy combined with systemic antibiotic therapy in 96% of the infected joints. One patient died due to esophageal bleeding.

In stage II, one arthroscopic decompression and irrigation was sufficient to cure the infection in 48% of the 44 infected joints, a second course of irrigation was necessary in 23%, a third in 23%, and a fourth in 6%. The mean interval between first and second irrigations was 3 days (range 1-7), and between the second and third irrigations 5 days (3-6). One patient needed additional open synovectomy because the infection could not be controlled arthroscopically. One patient with endocarditis and septic arthritis caused by bacterial dissemination died 7 days after arthroscopic irrigation in the course of the

Table 1 Affected joints

Joint	Stage I (n=22)	Stage II (n=44)	Stage III (n=12)	Total (n=78)
Knee	18	37	7	62
Shoulder	-	6	4	10
Ankle	3	1	1	5
Hip	1	-	-	1

Table 2 Cause of septic arthritis

Cause	Stage I (n=22)		Stage II (n=44)		Stage III (n=12)		Total (n=78)	
	n	%	n	%	n	%	n	%
Hematogenous	11	50	22	50	9	75	42	54
Postoperative	6	28	15	34	1	8	22	28
Open procedure	3	-	9	-	1	-	13	17
Arthroscopic procedure	3	-	6	-	-	-	9	11
Iatrogenic	4	18	5	11	2	17	11	14
Diagnostic puncture	1	-	1	-	1	-	3	4
Intra-articular steroids	3	-	4	-	1	-	8	10
Penetrating trauma	1	4	2	5	0	0	3	4

Table 3 Causative organisms

Organisms	Stage I (n=22)		Stage II (n=44)		Stage III (n=12)		Total (n=78)	
	n	%	n	%	n	%	n	%
Negative bacteriological result	5	22.8	11	24.9	1	8.3	17	21.8
<i>Staphylococcus aureus</i>	9	40.9	18	40.9	6	49.9	33	42.2
Streptococci	2	9.1	8	18.2	2	16.7	12	15.4
Pneumococci	1	4.5	2	4.5	2	16.7	5	6.4
<i>Escherichia coli</i>	1	4.5	2	4.5	-	-	3	3.8
<i>Staphylococcus epidermidis</i>	1	4.5	1	2.3	-	-	2	2.6
<i>Borrelia burgdorferi</i>	1	4.5	1	2.3	-	-	2	2.6
<i>Pseudomonas aeruginosa</i>	1	4.5	-	-	-	-	1	1.3
Enterococci	1	4.5	-	-	-	-	1	1.3
<i>Mycobacterium tuberculosis</i>	-	-	1	2.3	-	-	1	1.3
<i>Haemophilus influenzae</i>	-	-	-	-	1	8.3	1	1.3

disease. In the remaining patients arthroscopic therapy and systemic antibiotic therapy were sufficient to cure the septic arthritis (95%).

In stage III, one course of arthroscopic irrigation and débridement was sufficient to cure the infection in 3 of the 12 infected joints, a second arthroscopic procedure was necessary in 4, a third in 2, and a fourth in 1 joint. The mean interval between the first and second procedures was 3 days (range 1-6), and between the second and third procedures 6 days (2-7). Two patients with endocarditis and bacterial dissemination died, the one 5 days and the other 8 days after arthroscopic therapy. Two patients needed additional open synovectomy of the joints for the eradication of the infection, and in two patients secondary operations were necessary to treat the effects of the joint destruction (one total knee arthroplasty, one total ankle arthroplasty). In 67% of the stage III group arthroscopic irrigation and débridement combined with systemic antibiotic therapy were sufficient to cure the septic arthritis.

While a single arthroscopic irrigation was sufficient to cure most stage I infections, repeated irrigations were nec-

Table 4 Arthroscopic procedures in correlation to the stage of infection

Arthroscopic procedures	Stage I joints (n=22)	Stage II joints (n=44)	Stage III joints (n=12)	Total joints (n=78)
One	21	21	3	45
Two	1	10	5	16
Three	-	10	3	13
Four	-	3	1	4

essary in more than 50% of stage II or stage III infections (Fig. 1). As seen in Table 4, the number of necessary arthroscopies was correlated to the initial stage of infection.

Overall 91% of the 78 infected joints were cured with arthroscopic irrigation/débridement and systemic antibiotic therapy. However, the efficacy decreased with increasing severity of the initial stage of infection: 96% in stage I, 95% in stage II, and 67% in stage III (Fig. 1). In this study hardware (plates, screws, staples, wire) was used in ten patients: in four patients in stage I, five in stage II, and one in stage III. Removal of hardware was necessary only in one patient of the stage II group with an internal fixation of a fracture of the patella. Open revision was necessary in one stage II joint and in two stage III joints.

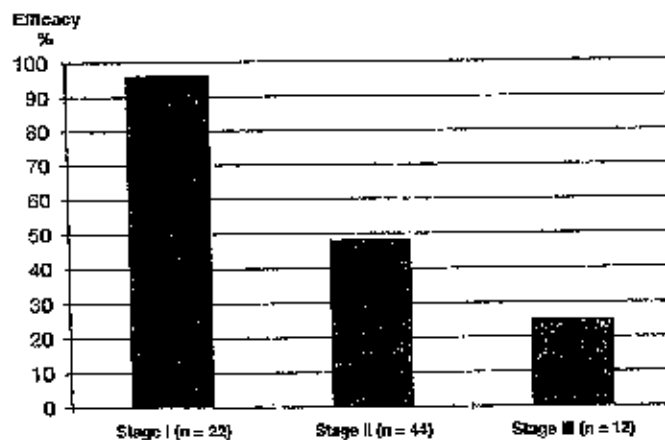


Fig. 1 Efficacy of the first arthroscopic irrigation

Discussion

The present study is one of the larger surveys analyzing the arthroscopic treatment of septic arthritis. Diagnostic arthroscopies without additional procedures seem to have a very low risk of infection, varying between 0.1 and 0.42% in the literature [2, 6, 32, 39]. Postoperative infections were found in 28% of our patient population (open procedures 17% and arthroscopic procedures 11%). Most of these patients were transferred from other hospitals.

The infection rate was found to increase with increasing operating time, increased number of procedures during surgery, prior procedures, and previous intra-articular steroid injections [2].

Ten percent of our patients showed an infection after intra-articular administration of steroids. Increased rates after intra-articular administration of steroids have been reported repeatedly in the literature [13, 15, 23]. Gray and Gottlieb [16] performed an experimental study on risks and benefits of intra-articular steroid injections. In their rabbit model systemic cortisone given daily 1 week before and 1 week after bacterial joint inoculation reduced the infecting dose of micrococcus 100,000-fold, while a single dose of intra-articular prednisolone given at the time of bacterial inoculation reduced the infecting dose 10,000-fold.

In the treatment of septic arthritis the proportion of bacteriological identifications varies from 63% to 100% [8, 12, 17, 27, 35]. The causative organism was identified in 78% of our patients, depending on the initial stage of infection. While 25% of stage I and II Gram stains were negative, all but one were positive in stage III infections. It is possibly that higher rates of identified causative organism could have been achieved by taking five tissue biopsy specimens, as recommended by Kamme and Lindberg [24]. As confirmed in other reports in the literature [2, 6, 27, 32, 35, 39], the most common organism identified in the present study was *Staphylococcus aureus*.

Clinical and experimental studies have shown a relationship between early and aggressive initiation of treatment and the success of therapy in septic arthritis [22, 26, 38]. Nord et al. [25] showed in a goat model that if an infected knee joint is diagnosed early, and appropriate antibiotic therapy is initiated immediately, arthrotomy and needle aspiration can effectively eradicate the infection, with only minimum damage to the cartilage. Despite the good results reported with repeated needle aspiration [14, 31] sufficient drainage of the joint by this method may be doubted [5, 7]. Some authors perform arthrotomy for the treatment of septic arthritis, with reportedly good results [3, 5]. The present data suggest that open revision and synovectomy are seldom necessary for most cases of septic arthritis and should be reserved for severe cases with concomitant osseous infection [12]. Good to excellent results of arthroscopic therapy of septic arthritis in infants and adults have been reported by several authors [9, 12, 17, 18, 20, 27, 33, 35, 36]. There is a general agreement about the necessity of a combination of arthroscopy and systemic antibiotics. Some authors also advocate intra-articular antibiotics [8, 9, 24, 27] while others refrain from the use of intra-articular antibiotic administration [4,

17, 30, 34, 36]. In the present study no antibiotics were added to the irrigation solution since several clinical and experimental studies have shown sufficient antibiotic levels in the synovial fluid after intravenous administration of antibiotics [8, 24, 28]. Furthermore Argen et al. [1] described a chemical synovitis after intra-articular instillation of antibiotics. Also, no antiseptic additives to the irrigation fluid were used in the present study because of reported toxicity to the articular cartilage with irreversible damage [12].

Jackson [18] has reported good results using a distension-irrigation technique in a small number of patients. Irrigation-suction drains have also been proposed by Parisien and Shaffer [27] and Gainer [9]. Several studies have found increased secondary infections and recurrences with the use of irrigation-suction drains [6, 29, 36]. The present study also showed that irrigation suction drains were not necessary.

For stage III infections débridement of necrotic material and adhesiolysis was performed with a shaver. We do not recommend a synovectomy initially, in order to preserve the synovial membrane as a barrier for the microorganisms [11, 12, 27]. In contrast to the recommendations of some authors [17, 18, 39], 41% of our patients needed repeated arthroscopic irrigations because of persistent infection. The rate of repeated arthroscopic procedures in the present study depended on the initial stage of the infection. Open revision was seldom needed (4%). We found an increased risk of therapy failure in the stage II and III groups. Thiery [36] reported in a multicenter study 10.9% failures and 10.9% recurrences in 46 patients. Ivey and Clark [17] prospectively studied the results of 13 adult patients treated with arthroscopic decompression, débridement, and shaving. They reported two failures and no recurrences.

In conclusion, arthroscopic decompression/irrigation combined with a systemic antibiotic regimen is an efficient way of treating septic arthritis. If symptoms of infection persist under antibiotic therapy, arthroscopic irrigation can be repeated with good results. The number of arthroscopic irrigations and the efficacy of treatment are influenced by the initial stage of infection. The shaver should be used for débridement of necrotic tissue and adhesiolysis only, and care should be taken to leave the synovial membrane intact. There is no indication for the intra-articular use of antibiotics because of possible chemical synovitis or antiseptic agents because of their cartilage toxicity. The use of wound drains is not necessary. Irrigation-suction drains are not recommended.

References

1. Argen RJ, Wilson CH, Wood P (1966) Suppurative arthritis. *Arch Intern Med* 117:661
2. Armstrong RW, Bolding F, Joseph R (1992) Septic arthritis following arthroscopy: clinical syndromes and analysis of risk factors. *Arthroscopy* 8:213-223
3. Ballard A, Burkhalter WE, Mayfield GW, DeLune E, Brown PW (1975) The functional treatment of pyogenic arthritis of the adult knee. *J Bone Joint Surg Am* 57:1119-1123
4. Broy SB, Schmid FR (1986) A comparison of medical drainage (needle aspiration) and surgical drainage (arthrotomy or arthroscopy) in the initial treatment of infected joints. *Clin Rheum Dis* 12:501-522
5. Bynum DK, Nunley JA, Goldner JL, Martinez S (1982) Pyogenic arthritis: emphasis on the need for surgical drainage of the infected joint. *South Med J* 75:1232-1237
6. D'Angelo GL, Ogilvie-Harris DJ (1988) Septic arthritis following arthroscopy, with cost/benefit analysis of antibiotic prophylaxis. *Arthroscopy* 4:10-14
7. Daniel D, Akeson W, Amiel D, Ryder M, Boyer J (1976) Lavage of septic joints in rabbits: effects of chondrolysis. *J Bone Joint Surg Am* 58:393
8. Fridmodt-Møller N, Riegels-Nielsen P (1987) Antibiotic penetration into the infected knee. A rabbit experiment. *Acta Orthop Scand* 58:256-259
9. Gänor BJ (1984) Insufflation of continuous tube irrigation in the septic knee at arthroscopy. *Clin Orthop* 183:96-98
10. Gächter A (1985) Der Gelenkinfekt. *Inform Arzt* 6:35-43
11. Gächter A (1993) Arthroscopic lavage for joint infections. *Orthopaed Traumatol* 2:104-106
12. Gächter A (1994) Gelenkinfekt. Arthroscopische Spülbehandlung - Hints und Tricks. *Arthroscopie* 7:98-101
13. Ginzler E, Meisel AD, Muniers, M Kaplan D (1979) Candida arthritis secondary to repeated intra-articular corticosteroids. *NY State J Med* 79:392-394
14. Goldenberg DL, Brandt KP, Cohen AS, Cathcart ES (1975) Treatment of septic arthritis. Comparison of needle aspiration and surgery as initial modes of joint drainage. *Arthritis Rheum* 18:83
15. Gottlieb NL, Riskin WG (1980) Complications of local corticosteroid injections. *JAMA* 243:1547-1548
16. Gray RG, Gottlieb NL (1977) Intra-articular corticosteroids. An updated assessment. *Clin Orthop* 177:235-263
17. Ivey M, Clark R (1985) Arthroscopic debridement of the knee for septic arthritis. *Clin Orthop* 199:201-206
18. Jackson RW (1985) The septic knee - arthroscopic treatment. *Arthroscopy* 1:194-197
19. Jackson RW, Parsons CJ (1973) Distension-irrigation treatment of major joint sepsis. *Clin Orthop* 96:160-164
20. Jarrett MP, Grossmann L, Sadler AH, Grayzel AI (1981) The role of arthroscopy in the treatment of septic arthritis. *Arthritis Rheum* 24:737
21. Kamme C, Lindberg L (1981) Aerobic and anaerobic bacteria in deep infections after total hip arthroplasty. *Clin Orthop* 154:201-207
22. Kelly PJ, Martin WJ, Coventry MB (1970) Bacterial (suppurative) arthritis in the adult. *J Bone Joint Surg Am* 52:1595-1598
23. Montgomery SC, Campbell J (1989) Septic arthritis following arthroscopy and intra-articular steroids. *J Bone Joint Surg Am* 71:540-545
24. Nelson JD (1971) Antibiotic concentrations in septic joint effusion. *N Engl J Med* 284:549-553
25. Nord KD, Dore DD, Decency VF, Armstrong AL, Cundy PJ, Cole BF, Ehrlich MG (1995) Evaluation of treatment modalities for septic arthritis with histological grading and analysis of levels of uronic acid, neutral protease, and interleukin-1. *J Bone Joint Surg Am* 77:258-265
26. Orchard RA, Stamp WC (1968) Early treatment of induced suppurative arthritis in rabbit knee joints. *Clin Orthop* 59:287-293
27. Parisien JS, Shaffer B (1992) Arthroscopic management of pyarthrosis. *Clin Orthop* 275:243-7
28. Patei H, Nade S (1988) Acute staphylococcal septic arthritis: the effect of cloxacillin therapy in an avian model. *J Orthop Res* 6:63-67
29. Riel KA, Primbs J, Bennett P (1994) Arthroscopische Überlaufspüldrainage bei akuter postoperativer Kniegelenkinfektion - Langzeitergebnisse. *Chirurg* 65:1023-1027
30. Schunmann DJ, Smith RL (1987) Surgical approach to the management of septic arthritis. *Orthop Rev* 16:241-245
31. Sharp JT, Lidsky MD, Duffy J, Duncan MW (1979) Infectious arthritis. *Arch Intern Med* 139:1125-1130
32. Sherman OH, Fox JM, Snyder SJ, et al (1986) Arthroscopy - "no-problem surgery." *J Bone Joint Surg Am* 68:256-265
33. Skyhar MJ, Mubarak SJ (1987) Arthroscopic treatment of septic knee in children. *J Pediatr Orthop* 7:647-653
34. Slama TG (1987) Treatment of septic arthritis. Diagnostic approach and rational use of antibiotics. *Orthop Rev* 16:236-240
35. Smith MJ (1986) Arthroscopic treatment of the septic knee. *Arthroscopy* 2:30-34
36. Thiery JA (1989) Arthroscopic drainage in septic arthritides of the knee: a multicenter study. *Arthroscopy* 5: 65-69
37. Travers V, Norotte G, Roger B, Apoll A (1988) Treatment of acute pyogenic arthritis of large joints of the limbs. *Rev Rhum Mal Osteoartic* 55:655-660
38. Ward J, Cohen AS, Bauer W (1960) The diagnosis and therapy of acute suppurative arthritis. *Arthritis Rheum* 3:522-529
39. Williams RJ, Laurencin CT, Warren RF, Speciale AC, Brause BD, O'Brien S (1997) Septic arthritis after arthroscopic anterior cruciate ligament reconstruction. Diagnosis and management. *Am J Sports Med* 25:261-267