

# CONSERVATIVE TREATMENT OF A FEMALE COLLEGIATE VOLLEYBALL PLAYER WITH COSTOCHONDRITIS

Donald Aspegren, DC,<sup>a</sup> Tom Hyde, DC,<sup>b</sup> and Matt Miller, MD<sup>c</sup>

## ABSTRACT

**Objective:** This study was conducted to discuss the conservative care used to treat a female collegiate volleyball player with acute costochondritis.

**Clinical Features:** A 21-year-old collegiate volleyball player had right anterior chest pain and midthoracic stiffness of 8 months duration.

**Intervention and Outcome:** High-velocity, low-amplitude manipulation was performed to the associated hypokinetic costovertebral, costotransverse, and intervertebral zygapophyseal thoracic joints. Instrument-assisted soft tissue mobilization was performed by using the Graston technique. Pain levels improved on numeric pain scale, as did functional status identified on Dallas Pain Questionnaire and Functional Rating Index.

**Conclusion:** This athlete seemed to respond positively to manipulation, soft tissue mobilization, and taping. (J Manipulative Physiol Ther 2007;30:321-325)

**Key Indexing Terms:** *Manipulation; Spinal; Athletic Injuries; Tietze's Syndrome; Chiropractic*

The participation of women in sports has steadily increased over recent decades because of the implementation of Title IX.<sup>1,2</sup> As participation increases, so does physical stress placed on the musculoskeletal system of the female athlete. Chest wall pain is a common symptom in athletes. Costochondritis typically presents as pain on the anterior chest wall of the costochondral or costosternal joints. This condition is more common in women<sup>3</sup> and associated with physical stresses experienced in athletics.<sup>4,5</sup> Costochondritis is typically a benign and self-limiting condition. However, other more ominous conditions such as *Escherichia coli* infection in the cartilage,<sup>6</sup> intravenous drug abuse,<sup>7</sup> primary tumors,<sup>7,8</sup> and rheumatologic disorders<sup>9</sup> are reported to be an associated cause of symptoms.

As soon as serious causes of anterior chest pain, such as cardiac<sup>10</sup> or pulmonary<sup>11</sup> issues, have been ruled out and the diagnosis of a benign etiology of costochondritis has been made, the management begins. The most commonly used

therapeutic approaches include reassurance,<sup>3</sup> acupuncture,<sup>12</sup> manual techniques,<sup>4,13,14</sup> steroid<sup>15</sup> or local anesthetic injections,<sup>16</sup> topical or oral analgesics, and the use of medications such as sulfasalazine.<sup>15</sup> Symptoms may persist for several months to several years but most commonly abate within 1 year.<sup>3,10</sup>

We present a case study of a female collegiate volleyball player with acute pain of the right fifth costocartilage, right second through fifth chondrosternal joints, and stiffness of the midthoracic region. A literature search of the Ovid and PubMed indices was performed. We present what we believe is the first published case of a collegiate volleyball player with costochondritis managed conservatively. Treatment included high-velocity, low-amplitude (HVLA) manipulation, Graston technique (GT), and Kinesio taping methods. The purpose of the article was to report the conservative treatment of costochondritis in a female collegiate athlete.

## CASE REPORT

A 21-year-old collegiate volleyball player presented with right anterior chest pain and midthoracic stiffness that had been present for 8 months. She played year-round in the United States and Europe and had begun this vigorous level of activity in high school. The anterior chest pain was constant and described by the patient as a sharp ache that worsened with volleyball and weightlifting. The weightlifting activities that exacerbated her pain were bench presses, bent flies, and power cleans. The patient denied respiratory or cardiac problems, and the onset of chest pain was reported to

<sup>a</sup> Private Practice, Director, Lakewood Spine and Sports Center, Lakewood, CO.

<sup>b</sup> Private Practice, North Miami Beach, FL.

<sup>c</sup> Private Practice, Director, Mile Hi Occupational Medicine.

No funding was received in the preparation of this paper.

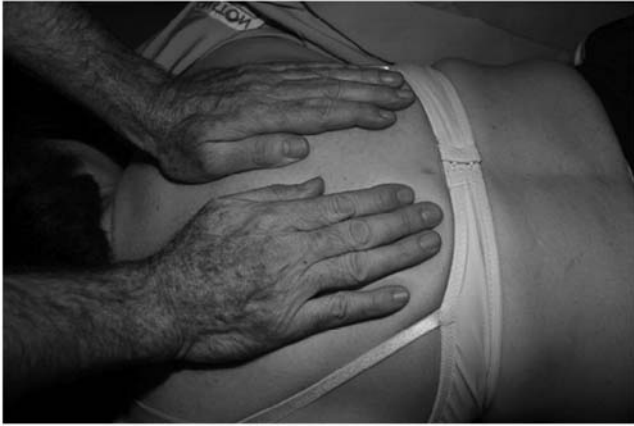Submit requests for reprints to: Donald Aspegren, DC, 11220 W. Colfax Ave, Lakewood, CO 80215, USA  
(e-mail: [dr.dda@comcast.net](mailto:dr.dda@comcast.net)).

Paper submitted July 31, 2006; in revised form January 1, 2007; accepted January 2, 2007.

0161-4754/\$32.00

Copyright © 2007 by National University of Health Sciences.

doi:10.1016/j.jmpt.2007.03.003



**Fig 1.** High-velocity, low-amplitude manipulation being applied to thoracic region.



**Fig 2.** Application of GT to costocartilage.

be insidious. Her quality of play had been adversely affected because of the pain. The pain made it difficult for her to focus in the classroom and obtain restful sleep. When pain levels increased during play, it became difficult to “dig” and “spike” balls. She had no prior treatments for this problem.

She marked her Numeric Pain Scale at a 7 on a 10-point scale. A Dallas Pain Questionnaire (DPQ)<sup>17,18</sup> demonstrated moderate pain levels with activities, with highest pain levels noted during lifting and movements experienced during practicing and playing volleyball. The DPQ is a 16-item visual analog tool developed for the purpose of evaluating a patient’s cognition of how chronic pain affects 4 aspects of their lives. These 4 categories are as follows: (1) daily activities, including pain and intensity, personal care, lifting, walking, sitting, standing, and sleeping; (2) work and leisure, including social life, traveling, and vocational; (3) anxiety-depression, including social life, traveling, and vocational; (4) social interest, which include interpersonal relationships, social support, and punishing responses. Initial DPQ scores were 60 for daily activities, 70 for work/leisure, 10 for anxiety/depression, and 0 for social activities. A Functional Rating Index (FRI)<sup>19</sup> found the patient reporting severe pain, with greatly disturbed sleep, and the ability to perform only 25% of her regular work/sport activities. The FRI is a self-reporting instrument consisting of 10 items, each with 5 possible responses that express graduating levels of disability. Regarding clinical use of the FRI tool, the average time required to complete it is 78 seconds. A higher score suggests more pain and a reduction in functional levels. Her initial FRI score was 22.


Acute pain was noted upon palpation and deep inspiration at the right fifth rib chondrosternal joint and the costochondral segment. Palpation tenderness in this region was graded 3 on a 4-point scale as per standards set forth by American College of Rheumatology in 1990.<sup>20</sup> A sternal compression test was acutely positive and painful at both the chondrosternal and costocartilage regions.<sup>21</sup> Shoulder

range of motion was within normal limits, but elevating the right arm through the range of motion reproduced symptoms in the chondrosternal and costocartilage areas and, to a lesser degree, in the dorsal region. Motion palpation revealed dysfunctional motion from the fifth through ninth costovertebral, costotransverse joints, and intervertebral segments. A bimanual spring test of the ribs yielded negative results.

A diagnostic ultrasound study was previously ordered by her primary care physician and offered an impression of benign nodules in the rib region. Results of a plain film chest radiograph were normal. A 3-phase bone scan ordered by the consulting orthopedic surgeon showed negative results.

The patient expressed a desire to avoid medications and/or injection therapy. Consequently, we approached the case using HVLA manipulation to the hypokinetic costovertebral, costotransverse joints, and intervertebral thoracic zygapophyseal (facet) joints (Fig 1). Audible cavitations, as described by Ross et al,<sup>22</sup> could be heard when performing manipulation to the involved spinal segments. Instrument-assisted soft tissue mobilization incorporating GT was gently applied to the chondrosternal joint and fifth costochondral segment (Fig 2). Kinesio tape was applied in 2 strips. First, a vertical strip (an I strip) was applied over the chondrosternal joints, and a second I strip was placed horizontally over the fifth costocartilage (Fig 3). The patient was initially treated twice a week for 2 weeks. After 2 weeks, she reported a subjective improvement in pain of “70%.” Sport participation was allowed to continue; however, weightlifting was initially suspended and reintroduced after several weeks. Pain stopped during volleyball play and decreased during nonparticipation periods.

High-velocity, low-amplitude spinal manipulation, GT, and Kinesio taping were performed on a weekly basis



**Fig 3.** Kinesio taping over chondral-sternal joints and costocartilages.

during the spring workouts to control pain and improve function of the previously described thoracic joints. We used 2 in Kinesio tape strips with no tension or stretch applied to the tape during application.<sup>23</sup> The patient was treated a total of 16 times. Pain scores at the end of treatment included an FRI score of 5; her FRI score on initial presentation was 22. Her Numeric Pain Scale score improved to 0.25 from a previous score of 7. Her DPQ improved; daily activities reduced from 60 to 6, work/leisure reduced from 70 to 10, anxiety/depression reduced from 10 to 0, social activities remained the same at 0. The athlete was able to continue participating as a volleyball player and fulfilled her athletic commitments to the university and her goals as a student-athlete. An extended treatment plan included care as needed for control of any increased symptoms and a 60-day rest period from play and weightlifting during the summer. Six months after discharge from care, the patient required no further treatment.

## DISCUSSION

Costochondritis is 1 of several chest wall conditions that commonly present to the emergency department. Disla et al<sup>10</sup> reported that of the 122 consecutive patients presenting to an emergency department with anterior chest wall pain, 36 (30%) had costochondritis. Of the 36, women accounted for 69% of those diagnosed with costochondritis. Brown and Jamil<sup>3</sup> studied 137 adolescents presenting with chest pain and found that 82% were afraid their pain was cardiac in origin. Of those who were concerned that a heart ailment was present, 29% continued to worry even after the diagnosis of costochondritis was made. Pantell and Goodman<sup>24</sup> prospectively analyzed 100 adolescents with chest pain and found that 56% believed their chest pain was due to a heart pathology. These authors further discuss that adolescents begin to perceive themselves as adults, consequently viewing themselves as vulnerable to adult diseases. In the case study

we present, a significant history of breast cancer was in the family and of concern to this student-athlete.

Physical examination findings for costochondritis typically include anterior chest wall tenderness that is localized to the costochondral junction of 1 or more ribs, but does not include swelling, heat, or erythema.<sup>5</sup> The second through fifth costal cartilage areas are most commonly involved. Associated restriction of corresponding costovertebral and costotransverse joints may be discovered on joint play assessment,<sup>13</sup> such as by motion palpation.<sup>25,26</sup> Motion palpation is a manual process of moving a joint into its maximal end range of motion, after which it is challenged with a light springing movement. This end point of joint movement forms the basis for determination of a normal or abnormal joint play. Reduced motion of the joint is considered fixated or hypokinetic.<sup>27</sup> Hypokinetic motion of the second and fifth costovertebral, costotransverse, and facet joints was detected in our patient. The loss of normal spinal movement and associated chest pain was recently described by Yelland,<sup>28</sup> who observed thoracic intervertebral dysfunction by using active movement and applying an intersegmental overpressure to the zygapophyseal joints. An examiner who was blinded to pertinent details identified intervertebral dysfunction in only 25% of controls, whereas 79% of patients with thoracic and associated chest pain were identified as having alterations in spinal intersegmental motion.

Plain film radiography is normally used in costochondritis, although mild soft tissue swelling may be present. Ontell et al<sup>8</sup> describe radiographic and computerized tomography scan features of costochondritis that may include chondral enlargement or destruction, low attenuation of the costal cartilage (observed on computerized tomography), and soft tissue swelling. Three-phase bone scan may offer a hotspot of a costochondral junction that may be asymptomatic.<sup>5</sup> Imaging for the presented volleyball player did not yield remarkable results. Most studies fail to describe laboratory findings; however, Disla et al<sup>10</sup> reported elevated sedimentation rates in patients with costochondritis. Our patient's sedimentation rate was normal with no abnormalities found in the complete blood count or differential.

The main therapeutic approaches involved in our case includes reassurance,<sup>3</sup> HVLA manipulation of costovertebral,<sup>14</sup> costotransverse,<sup>13</sup> and intervertebral zygapophyseal (facet) joints,<sup>28</sup> GT<sup>29</sup> applied directly to the costal cartilage, and Kinesio taping<sup>30</sup> of the fifth costal cartilage and along the third through sixth chondrosternal joints. The subject's weightlifting workouts were altered, excluding bench pressing and flies. We allowed the athlete to continue playing volleyball.

Rumball et al<sup>4</sup> recently described the mechanisms of rowing as a mechanical factor leading to the development of costochondritis. They believe inflammation in the costochondral region is most likely caused by an increase in pulling from adjoining muscles to the rib or a dysfunction at the costotransverse joint of the involved rib. In the



**Fig 4.** *Stainless steel instruments used in GT.*

symptomatic rowers, arm adduction of the involved side, coupled with head rotation toward the involved side, reproduced symptoms.<sup>4</sup> This described motion is descriptive of the follow-through motion of a volleyball player as they spike the ball. Follow-through motion brings the arm across the body while the head approximates the shoulder of the adducting arm. The volleyball player presented in this case was right-handed and experienced right-sided costochondritis.

The observed costotransverse joint dysfunction observed in rowers<sup>4</sup> with costochondritis was also found in our volleyball player. Whether this finding is a factor in causation or a secondary manifestation is unclear. However, Erwin et al<sup>14</sup> concluded that the costovertebral joint has been considered a candidate for producing a chest pain referred to as a “pseudoangina” that may be ameliorated by spinal manipulation. We did incorporate HVLA spinal manipulation directed at hypokinetic costovertebral, costotransverse, and dysfunctional intersegmental zygapophyseal joints into our treatment approach.

Many studies have been conducted on the effectiveness of manipulation<sup>31-36</sup> and, as Triano<sup>37</sup> reported, most have been conducted using HVLA methods. During HVLA spinal manipulation, peak amplitude has been demonstrated to range from 41 to 889 N. Applied forces rise quickly with slopes ranging between 519 to 2907 N/s.<sup>37</sup> The use of these forces with HVLA manipulation is commonly directed at a functional spinal lesion believed to exist (in our case) at costovertebral, costotransverse, and zygapophyseal joints. The goal of using HVLA manipulation was to reestablish normal preinjury distribution of mechanical loads through the targeted spinal articular structures identified in this case, and to ameliorate irritation to associated costocartilage, costochondral, and chondrosternal joints. By attempting to reestablish normal motion, healing is promoted in nociceptive pain generators through a dissipation of pathologic stress and a return to normal activity.

Also included in the treatment approach of this patient was the incorporation of GT, an instrument-assisted soft-tissue technique using 6 patented stainless steel instruments (Fig 4). These instruments are concave and convex with single and double beveled edges. The concave and convex surfaces allow for greater contact over irregular body parts. In the application of the technique, the instruments are

passed over the area of pain at a 30° to 60° angle in the direction of the beveled edge for 60 to 120 s. During this application time, the clinician attempts to locate “gritty, gravelly, sandy” types of sensations that are amplified back to the patient and clinician through the instrument.<sup>38</sup> Sevier and Wilson<sup>39</sup> state that the instruments are moved primarily in longitudinal strokes over the involved musculotendinous structures by using multidirectional strokes. Passing the instruments over injured regions will produce an inflammatory response and result in the destruction of existing scar tissue.<sup>40</sup> It has also been stated that many athletes develop excessive connective tissue fibrosis (scar tissue) or poorly organized scar tissue in and around muscles, tendons, ligaments, joints, and myofascial planes as a result of acute trauma, recurrent microtrauma, immobilization, or as a complication of surgical intervention.<sup>40</sup>

During the initial application of GT to the symptomatic costochondral region of the patient, a gritty sensation was identified. As the patient improved, the amount of “gritty” sensation decreased. Melham et al<sup>40</sup> hypothesized that the use of the GT instruments break down existing scar tissue in patients with chronic pain and begins the formation of new scar tissue activity with the fibroblast laying down new scar tissue in parallel, as opposed to laying down of this tissue in random. Gentle stretching is applied after treatment to assist in the formation of new organized scar tissue. The formation of parallel connective tissue fiber formation might be analogous to trabecular patterns of stress commonly observed in bone tissue.

Kinesio taping has recently been shown to improve upper-extremity control and function in the acute pediatric rehabilitation setting. Motor skills and functional performance improved in the region where Kinesio taping was applied.<sup>30</sup> We used Kinesio tape over the involved fifth costal cartilage and over the second through fifth chondrosternal joints. The desired effect was to assist in local motor skill and functional improvement of activity to reduce irritation to the cartilage. The application of the Kinesio tape seemed to enhance proprioceptive function to reduce irritation during activities. The athlete reported being more aware of the stress she applied to the costocartilage while playing. Another desired effect, as described in the Kinesio tape manual,<sup>23</sup> was to improve lymph flow from the injured area. In the physical examination findings, a boggiess was noted over the patient’s costocartilage and chondrosternal regions. As also described in the manual, pain will commonly decrease with improvement in lymphatic flow from the injured region. The patient noted improvement in pain and functional performance levels during and after wearing the tape as shown in Figure 1. The patient wore the tape between visits to our office. As she became less symptomatic, the benefits of Kinesio tape seemed to decrease. The benefits seemed most pronounced while the patient was in the more acute stage of her condition and the boggiess over the costocartilage and chondrosternal joints was most pronounced.

## CONCLUSION

Costochondritis is a common condition of the anterior chest wall that may compromise an athlete's performance levels. Various methods of treatment are available but infrequently documented in athletes. Studies within various venues of sports are indicated to better understand the incidence and prevalence of this potentially performance-altering condition.

## REFERENCES

1. Lopiano DA. Modern history of women in sports. Twenty-five years of I.X. Title. *Clin Sports Med* 2000;19:163-73,vii.
2. Thein LA, Thein JM. The female athlete. *J Orthop Sports Phys Ther* 1996;23:134-48.
3. Brown RT, Jamil K. Costochondritis in adolescents. A follow-up study. *Clin Pediatr (Phila)* 1993;32:499-500.
4. Rumball JS, Lebrun CM, Di Ciacca SR, Orlando K. Rowing injuries. *Sports Med* 2005;35:537-55.
5. Gregory PL, Biswas AC, Batt ME. Musculoskeletal problems of the chest wall in athletes. *Sports Med* 2002;32:235-50.
6. Ogden J, Alvarez RG, Cross GL, Jaakkola JL. Plantar fasciopathy and orthotripsy: the effect of prior cortisone injection. *Foot Ankle Int* 2005;26:231-3.
7. Meyer CA, White CS. Cartilaginous disorders of the chest. *Radiographics* 1998;18:1109-23 [quiz 1241-2].
8. Ontell FK, Moore EH, Shepard JA, Shelton DK. The costal cartilages in health and disease. *Radiographics* 1997;17:571-7.
9. Mukerji B, Mukerji V, Alpert MA, Selukar R. The prevalence of rheumatologic disorders in patients with chest pain and angiographically normal coronary arteries. *Angiology* 1995;425-30.
10. Disla E, Rhim HR, Reddy A, Karten I, Taranta A. Costochondritis. A prospective analysis in an emergency department setting. *Arch Intern Med* 1994;154:2466-9.
11. Lin EC. Costochondritis mimicking a pulmonary nodule on FDG positron emission tomographic imaging. *Clin Nucl Med* 2002;27:591-2.
12. Li B. 106 cases of non-suppurative costal chondritis treated by acupuncture at Xuanzhong point. *J Tradit Chin Med* 1998;18:195-6.
13. Fruth SJ. Differential diagnosis and treatment in a patient with posterior upper thoracic pain. *Phys Ther* 2006;86:254-68.
14. Erwin WM, Jackson PC, Homonko DA. Innervation of the human costovertebral joint: implications for clinical back pain syndromes. *J Manipulative Physiol Ther* 2000;23:395-403.
15. Freeston J, Karim Z, Lindsay K, Gough A. Can early diagnosis and management of costochondritis reduce acute chest pain admissions? *J Rheumatol* 2004;31:2269-71.
16. Jensen TW. Vertebrobasilar ischemia and spinal manipulation. *J Manipulative Physiol Ther* 2003;26:443-7.
17. Lawlis GF, Cuencas R, Selby D, McCoy CE. The development of the Dallas Pain Questionnaire. An assessment of the impact of spinal pain on behavior. *Spine* 1989;14:511-6.
18. Andersen T, Christensen FB, Bunger C. Evaluation of a Dallas Pain Questionnaire classification in relation to outcome in lumbar spinal fusion. *Eur Spine J* 2006;1-15.
19. Feise RJ, Michael Menke J. Functional rating index: a new valid and reliable instrument to measure the magnitude of clinical change in spinal conditions. *Spine* 2001;26:78-86 [discussion 87].
20. Buskila D, Neumann L, Vaisberg G, Alkalay D, Wolfe F. Increased rates of fibromyalgia following cervical spine injury. A controlled study of 161 cases of traumatic injury. *Arthritis Rheum* 1997;40:446-52.
21. Evans RC. *Illustrated orthopedic physical assessment*. St Louis: Mosby Inc; 2001.
22. Ross JK, Bereznick DE, McGill SM. Determining cavitation location during lumbar and thoracic spinal manipulation: is spinal manipulation accurate and specific? *Spine* 2004;29:1452-7.
23. *Kinesio Taping Perfect Manual*. Durham, NC: Universal Printing and Publishing; 1998.
24. Pantell RH, Goodman BW. Adolescent chest pain: a prospective study. *Pediatrics* 1983;71:881-7.
25. Humphreys BK, Delahaye M, Peterson CK. An investigation into the validity of cervical spine motion palpation using subjects with congenital block vertebrae as a 'gold standard'. *BMC Musculoskelet Disord* 2004;5:19.
26. Pringle RK. Guidance hypothesis with verbal feedback in learning a palpation skill. *J Manipulative Physiol Ther* 2004;27:36-42.
27. Hansen BE, Simonsen T, Leboeuf-Yde C. Motion palpation of the lumbar spine—a problem with the test or the tester? *J Manipulative Physiol Ther* 2006;29:208-12.
28. Yelland MJ. Back, chest and abdominal pain. How good are spinal signs at identifying musculoskeletal causes of back chest or abdominal pain? *Aust Fam Physician* 2001;30:908-12.
29. Hammer WI, Pfefer MT. Treatment of a case of subacute lumbar compartment syndrome using the Graston technique. *J Manipulative Physiol Ther* 2005;28:199-204.
30. Yasukawa A, Patel P, Sisung C. Pilot study: investigating the effects of Kinesio taping in an acute pediatric rehabilitation setting. *Am J Occup Ther* 2006;60:104-10.
31. Hurwitz EL, Morgenstern H, Kominski GF, Yu F, Chiang LM. A randomized trial of chiropractic and medical care for patients with low back pain: eighteen-month follow-up outcomes from the UCLA low back pain study. *Spine* 2006;31:611-21 [discussion 622].
32. Sherman KJ, Cherkin DC, Deyo RA, et al. The diagnosis and treatment of chronic back pain by acupuncturists, chiropractors, and massage therapists. *Clin J Pain* 2006;22:227-34.
33. Cherkin DC, Sherman KJ, Deyo RA, Shekelle PG. A review of the evidence for the effectiveness, safety, and cost of acupuncture, massage therapy, and spinal manipulation for back pain. *Ann Intern Med* 2003;138:898-906.
34. Gross AR, Hoving JL, Haines TA, et al. A Cochrane review of manipulation and mobilization for mechanical neck disorders. *Spine* 2004;29:1541-8.
35. Bronfort G, Haas M, Evans RL, Bouter LM. Efficacy of spinal manipulation and mobilization for low back pain and neck pain: a systematic review and best evidence synthesis. *Spine J* 2004;4:335-56.
36. Cooperstein R, Perle SM, Gatterman MI, Lantz C, Schneider MJ. Chiropractic technique procedures for specific low back conditions: characterizing the literature. *J Manipulative Physiol Ther* 2001;24:407-24.
37. Triano JJ. Biomechanics of spinal manipulative therapy. *Spine J* 2001;1:121-30.
38. Carey T, Hammer W, Vincent R, et al. *The Graston technique instructional manual*. 2nd ed. Indianapolis: Therapy Care Resources; 2001.
39. Sevier TL, Wilson JK. Treating lateral epicondylitis. *Sports Med* 1999;28:375-80.
40. Melham TJ, Sevier TL, Malnofski MJ, Wilson JK, Helfst RH. Chronic ankle pain and fibrosis successfully treated with a new noninvasive augmented soft tissue mobilization technique (ASTM): a case report. *Med Sci Sports Exerc* 1998;30:801-4.