

American Journal of Sports Medicine

<http://ajs.sagepub.com>

Low-Intensity Pulsed Ultrasound Accelerates and a Nonsteroidal Anti-inflammatory Drug Delays Knee Ligament Healing

Stuart J. Warden, Keith G. Avin, Erin M. Beck, Marie E. DeWolf, Molly A. Hagemeyer and Kristin M. Martin
Am. J. Sports Med. 2006; 34; 1094 originally published online Feb 13, 2006;
DOI: 10.1177/0363546505286139

The online version of this article can be found at:
<http://ajs.sagepub.com/cgi/content/abstract/34/7/1094>

Published by:

 SAGE Publications

<http://www.sagepublications.com>

On behalf of:



[American Orthopaedic Society for Sports Medicine](#)

Additional services and information for *American Journal of Sports Medicine* can be found at:

Email Alerts: <http://ajs.sagepub.com/cgi/alerts>

Subscriptions: <http://ajs.sagepub.com/subscriptions>

Reprints: <http://www.sagepub.com/journalsReprints.nav>

Permissions: <http://www.sagepub.com/journalsPermissions.nav>

Citations (this article cites 34 articles hosted on the
SAGE Journals Online and HighWire Press platforms):
<http://ajs.sagepub.com/cgi/content/abstract/34/7/1094#BIBL>

Low-Intensity Pulsed Ultrasound Accelerates and a Nonsteroidal Anti-inflammatory Drug Delays Knee Ligament Healing

Stuart J. Warden,* BPhysio (Hons), PhD, Keith G. Avin, MS, Erin M. Beck, PTA, Marie E. DeWolf, ATC, Molly A. Hagemeyer, and Kristin M. Martin
From the Department of Physical Therapy, Indiana University, Indianapolis, Indiana

Background: Low-intensity pulsed ultrasound and nonsteroidal anti-inflammatory drugs are used to treat ligament injuries; however, their individual and combined effects are not established.

Hypotheses: Low-intensity pulsed ultrasound accelerates ligament healing, a nonsteroidal anti-inflammatory drug delays healing, and the nonsteroidal anti-inflammatory drug inhibits the beneficial effect of low-intensity pulsed ultrasound.

Study Design: Controlled laboratory study.

Methods: Sixty adult rats underwent bilateral transection of their knee medial collateral ligaments. Animals were divided into 2 drug groups and treated 5 d/wk with celecoxib (5 mg/kg) mixed in a vehicle solution (NSAID group) or vehicle alone (VEH group). One to 3 hours after drug administration, all animals were treated with unilateral active low-intensity pulsed ultrasound and contralateral inactive low-intensity pulsed ultrasound. Equal numbers of animals from each drug group were mechanically tested at 2 weeks (n = 14/group), 4 weeks (n = 8/group), and 12 weeks (n = 8/group) after injury.

Results: Ultrasound and drug intervention did not interact to influence ligament mechanical properties at any time point. After 2 weeks of intervention, ligaments treated with active low-intensity pulsed ultrasound were 34.2% stronger, 27.0% stiffer, and could absorb 54.4% more energy before failure than could ligaments treated with inactive low-intensity pulsed ultrasound, whereas ligaments from the NSAID group could absorb 33.3% less energy than could ligaments from the VEH group. There were no ultrasound or drug effects after 4 and 12 weeks of intervention.

Conclusions: Low-intensity pulsed ultrasound accelerated but did not improve ligament healing, whereas the nonsteroidal anti-inflammatory drug delayed but did not impair healing. When used in combination, the beneficial low-intensity pulsed ultrasound effect was cancelled by the detrimental nonsteroidal anti-inflammatory drug effect.

Clinical Relevance: Low-intensity pulsed ultrasound after ligament injury may facilitate earlier return to activity, whereas nonsteroidal anti-inflammatory drugs may elevate early reinjury risk.

Keywords: biomechanics; ligament healing; medial collateral ligament (MCL); therapeutic ultrasound

Ligament injuries pose substantial problems for athletes, both acutely in terms of time lost from participation and chronically in terms of joint laxity and degenerative joint disease. The major goal of clinicians when treating acute ligament injuries is to return athletes to their preinjury

level of function, ideally in the shortest time possible and without compromising tissue-level healing. Two methods frequently used to facilitate this goal are the application of ultrasound therapy and the taking of nonsteroidal anti-inflammatory drugs (NSAIDs).

Ultrasound therapy is used after acute ligament injury in an attempt to accelerate healing. In a recent survey, 95% of physical therapists reported using ultrasound when managing acute ligament injuries.³⁰ Therapists reported using it to increase tissue extensibility and stimulate collagen production. Despite its frequent use, there is minimal scientific evidence to support a beneficial effect of ultrasound. Reviews of its effects have repeatedly concluded that there is insufficient evidence to support the current application of

*Address correspondence to Stuart J. Warden, BPhysio (Hons), PhD, Department of Physical Therapy, Indiana University, 1140 W. Michigan Street, CF-326, Indianapolis, IN 46202 (e-mail: stwarden@iupui.edu).

One or more authors has declared a potential conflict of interest: reimbursement for attending a symposium.

ultrasound.^{1,9,20,25} To address this issue, a new direction for ultrasound therapy in sports medicine has recently been proposed.²⁷ This direction was stimulated by research demonstrating that ultrasound can have clinically significant beneficial effects on injured tissue when low-intensity pulsed ultrasound (LIPUS) is used.²⁸ *Low-intensity pulsed ultrasound* refers to pulsed-wave ultrasound with a spatial-averaged, temporal-averaged intensity (I_{SATA}) equal to or lower than 100 mW/cm². This dose is alternative to that traditionally used in sports medicine, and preliminary research has demonstrated that this new direction in ultrasound therapy may be beneficial in the treatment of acute ligament injuries.²⁴

In contrast to ultrasound therapy, the basic tenet for NSAID use after acute musculoskeletal injury is to limit the amount and duration of inflammation and to control pain. Although inflammation is an important step in tissue healing, complications can arise and secondary tissue damage can be generated; NSAIDs introduced after an acute injury may limit this step as well as facilitate the commencement of active rehabilitation by alleviating pain. Although NSAIDs have become somewhat synonymous with the management of acute injuries, their efficacy has yet to be proven. This issue is of particular concern in view of recent research indicating potential detrimental tissue effects of 1 class of NSAIDs—selective cyclooxygenase-2 (COX-2) inhibitors.²⁶ Cyclooxygenase-2 is an enzyme involved in the production of prostaglandins after acute injury. Because prostaglandins cause blood vessel dilation and increase local vascular permeability to potentiate inflammation,⁴ inhibition of COX-2 is considered to be useful after acute injury. However, this belief has been questioned,²⁶ with recent research showing the use of a selective COX-2 inhibitor to potentially reduce acute ligament healing.⁷

In addition to studying the individual effects of LIPUS therapy and NSAIDs on ligament repair, it is also important to investigate their effects in combination. A possible pathway by which LIPUS may have beneficial effects on ligament repair is through the stimulation of COX-2.^{15,21,29} By studying the 2 agents in combination, mechanistic information regarding the possible pathway of action for LIPUS may be gained. This may provide valuable information regarding the combined clinical use of these 2 agents during acute ligament repair.

The aim of the current study was to investigate the individual and combined effects of LIPUS and an NSAID (a selective COX-2 inhibitor) on acute ligament healing in an animal model. It was hypothesized that LIPUS would accelerate repair, the NSAID would delay repair, and the NSAID would inhibit the beneficial influence of LIPUS, as determined via tests on ligament mechanical properties.

MATERIALS AND METHODS

Study Design and Animals

The design of this controlled laboratory study is illustrated in Figure 1. Sixty adult, virgin, female Sprague-Dawley rats (weight, 250-300 g) were purchased from Harlan

Sprague-Dawley Inc (Indianapolis, Ind) and acclimatized for 2 weeks before experimentation. Animals had ad libitum access to standard rat chow and water at all times. All procedures were performed in accordance with institutional animal care and use committee guidelines.

Ligament Injury

All animals underwent surgery on entry to the study to create bilateral knee medial collateral ligament (MCL) injuries. After a preoperative subcutaneous dose of buprenorphine hydrochloride analgesia (0.05 mg/kg; Buprenex, Reckitt & Colman Pharmaceuticals Ltd, Richmond, Va), surgical anesthesia was achieved using a mixture of ketamine (60-80 mg/kg; Ketaset, Fort Dodge Animal Health, Fort Dodge, Iowa) and xylazine (7.5 mg/kg; Sedazine, Fort Dodge Animal Health) introduced intraperitoneally. With a sterile technique, a 5-mm longitudinal incision was made over 1 knee medial joint line, and the MCL was located and sharply transected at the joint line. The skin incision was closed using a single subcuticular absorbable suture. The procedure was repeated on the contralateral side to create bilateral injuries. The hindlimb that was operated on first in each animal was alternated to reduce surgical bias.

Drug Intervention

Animals were randomly allocated to 2 drug groups (NSAID and VEH groups) (Figure 1). The interventions were commenced immediately after surgery and introduced 5 d/wk. The NSAID group was given celecoxib (Celebrex, Pfizer Inc, New York, NY) via oral gavage at a dose of 5 mg/kg. Celecoxib is a selective COX-2 inhibitor with a COX-1/COX-2 IC₅₀ ratio of 17, indicating that the dose of celecoxib required to inhibit the activity of COX-2 by 50% is 17 times less than that required to inhibit COX-1 activity by 50%.²⁶ The celecoxib dose introduced was equivalent to that used clinically to treat acute pain in humans (400 mg/70 kg),²⁶ with the pharmacokinetics of celecoxib in terms of its half-life ($t_{1/2}$) being similar in female rats ($t_{1/2} = 14.0$ h)¹⁸ as in humans ($t_{1/2} = 11.5$ h).¹⁷ Celecoxib was dissolved in a vehicle of polyethylene glycol (PEG) and saline (2:1, v/v) to form a solution of 3 mg/mL for delivery. The VEH group received only the delivery vehicle (PEG and saline; 2:1, v/v) without the active drug, which was given via oral gavage at an equal volume as in the NSAID group.

Ultrasound Intervention

One to 3 hours after NSAID intervention, animals in both drug groups were treated with LIPUS. Oral administration of celecoxib to rats leads to peak plasma and tissue levels after 1 hour,¹⁸ coincident with LIPUS intervention. Each animal was treated unilaterally with active LIPUS and contralaterally with inactive LIPUS (Figure 1). For intervention, animals were anesthetized using isoflurane inhalation (3% at 1.5 L/min for initial knockdown in a plastic container, and 1.5% at 1.5 L/min via a face mask for maintenance of anesthesia). Active LIPUS was produced by the Accusonic LIPUS GS 170 (Metron Medical Australia Pty Ltd, Carrum

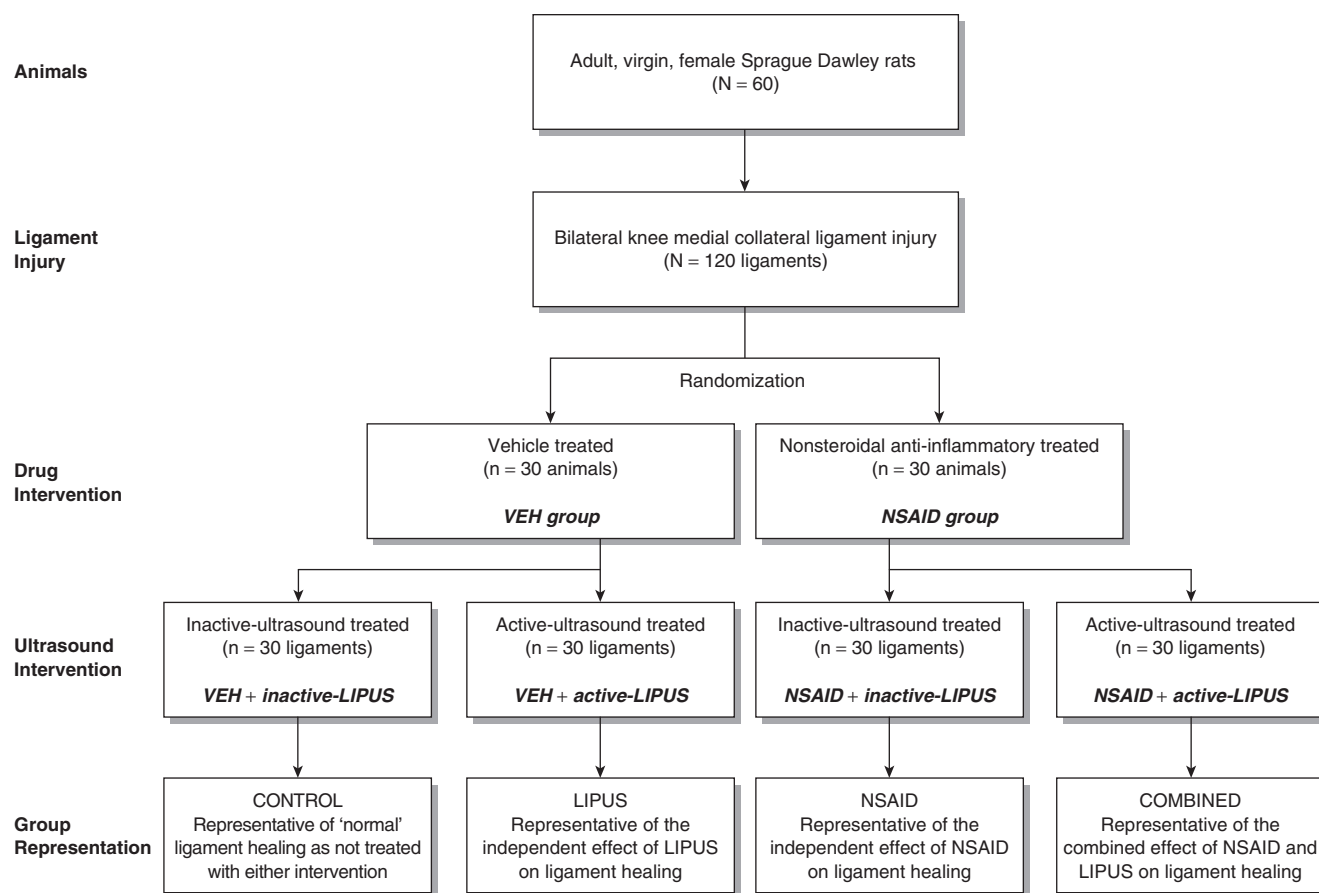


Figure 1. Study design. VEH, vehicle-treated; NSAID, nonsteroidal anti-inflammatory drug; LIPUS, low-intensity pulsed ultrasound.

Downs, Australia) (Figure 2), which produces a 2-millisecond burst of 1.0-MHz sine waves repeating at 100 Hz. The I_{SATA} on this unit is set at 100 mW/cm^2 , which refers to the average ultrasound output over the area of the ultrasound beam (spatial average) and the average of this intensity over a complete pulse cycle (ultrasound "on" and "off" period; temporal average). According to the manufacturer, the transducer had an effective radiating area and beam nonuniformity ratio of 5 cm^2 and less than 6.0, respectively. Ultrasound unit performance was confirmed at weekly intervals using a power meter (UPM-DT-1, Ohmic Instruments, Easton, Md). Active and inactive LIPUS were coupled with the skin using standard ultrasound gel (Aquasonic 100, Parker Laboratories Inc, Fairfield, NJ) and introduced daily for 20 minutes, 5 d/wk. The animals' fur was clipped at weekly intervals to facilitate ultrasound propagation. The LIPUS parameters and treatment time were chosen based on those shown to be beneficial during the healing of acute tissue injuries (see Warden²⁷ for review).

Assessment Time Points and Specimen Preparation

Equal numbers of animals from each drug intervention group were sacrificed at 2 weeks (n = 14/group), 4 weeks (n = 8/group), and 12 weeks (n = 8/group) after surgery by

inhalation of anesthetic gases followed by cervical dislocation. These group numbers were chosen because they have been shown in previous studies to be sufficient for the detection of significant drug⁷ and ultrasound²⁴ effects in the animal model being used. More animals were sacrificed at 2 weeks in anticipation of reduced statistical power due to ligament damage during dissection and testing of the immature scars at this early healing time point. After death, the left and right hindlimbs were harvested and stored at -80°C with the knee tissues intact. (Postmortem storage of ligaments by freezing does not influence their mechanical properties.³²) On the day of mechanical testing, the hindlimbs were allowed to thaw to room temperature in phosphate-buffered saline (PBS). The MCLs were tested with intact femoral and tibial insertions. Femoral-MCL-tibia (FMT) complexes were prepared from specimens by dissecting clear extraneous tissue while keeping the ligament and insertion sites hydrated with PBS. The proximal tibial growth plate was removed, and each FMT complex was placed in a customized testing jig with the knee joint positioned in 70° of flexion for MCL testing. This position appears to load all ligament fibers simultaneously.¹⁹ The jig was coupled to an electromagnetic materials testing device (TestBench 200 N ELF LM-1, EnduraTEC Systems Group, Bose Corp, Minnetonka, Minn) equipped with a 50-N load



Figure 2. Accusonic LIPUS GS 170 ultrasound unit (Metron Medical Australia Pty Ltd, Carrum Downs, Australia).

cell. This system possesses a force and displacement resolution of 0.01 N and 0.001 mm, respectively. A preload of 0.05 N was applied to each ligament. The ligaments were preconditioned by cyclically loading at 1 Hz for 10 cycles to 1% strain to reduce the effect of deep freezing on the low-load properties of the ligament.³² The ligament was unloaded and allowed to recover for 5 minutes while being kept moist with PBS.

Ligament Mechanical Properties

After tissue recovery, preload (0.05 N) was re-established, and the ligaments were pulled to tensile failure in displacement control at a strain rate of 0.8 mm/s (~10% per second). During testing, force and displacement data were collected at 100 Hz. The location of ligament failure was observed, and from the force-displacement curves, the mechanical properties of ultimate force, stiffness, and energy to failure were obtained (Figure 3).

Statistical Analyses

Body weights were compared between drug groups (NSAID vs VEH) and over time (2 vs 4 vs 12 weeks) using a 2-factorial analysis of variance (ANOVA). Chi-squared analyses were performed to assess intervention (drug and ultrasound) and time effects on the location of ligament failure during testing. Intervention effects on ligament mechanical properties at each time point were determined using 2-way, 1 repeated-measure ANOVAs, with drug intervention (NSAID vs VEH) being the between-animal independent variable and ultrasound intervention (active vs inactive LIPUS) being the within-animal independent variable. In the event of a non-significant interaction between the interventions, the main effect for each (drug and ultrasound) was explored. This method effectively doubled group sizes, as it averaged the effect of the individual intervention across the levels of the other intervention. Ultrasound main effects were determined

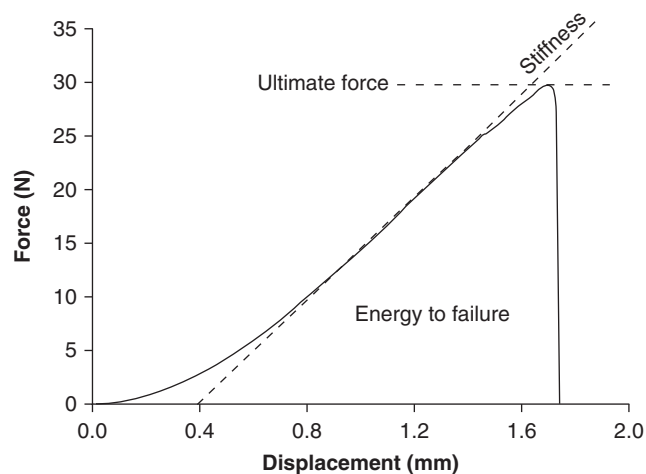


Figure 3. Representative force-displacement curve generated from a medial collateral ligament test. Mechanical properties derived from this graph included ultimate force (peak of the curve on the y-axis), stiffness (slope of the linear portion of the curve), and energy to failure (area under the curve).

using mean percentage differences and their 95% confidence intervals (CIs) between ligaments treated with active and inactive LIPUS, whereas drug main effects were assessed using mean differences and their 95% CIs between NSAID- and VEH-treated animals. Analyses were performed using the Statistical Package for Social Sciences (SPSS 6.1.1, Norusis/SPSS Inc, Chicago, Ill), and all comparisons were 2-tailed with a level of significance set at .05.

RESULTS

There were no operative or postoperative complications. There was no interaction between drug and time since injury ($P = .72$) and no drug main effect on body weight ($P = .45$); however, animals treated for 12 weeks were significantly heavier at death than were those treated for 2 weeks ($P < .05$). All surgical defects were bridged with scar tissue at the time of dissection. After 2 weeks of intervention, there was visible ligament hypertrophy, and the injured region was clearly distinguishable from the uninjured ligament tissue by its pinkish, mucoid appearance (Figure 4A). After 4 weeks of intervention, the ligaments were smaller and their scars better organized than after intervention for 2 weeks; however, the scar region remained larger than the uninjured portions of the ligament (Figure 4B). In comparison, ligaments after 12 weeks of intervention had difficult-to-see whitish scars that were relatively indistinguishable from the uninjured tissue, and the thickness of the scar region was continuous with that of the uninjured portions of the ligament (Figure 4C). At all time points, there were no grossly observable differences between ligaments treated with active versus inactive LIPUS or from animals in the NSAID versus VEH groups. Similarly, neither intervention influenced the location of ligament failure during testing ($P > .05$); however, significantly more ligaments failed at the scar (as opposed to the femoral and tibial insertions) in the groups treated for

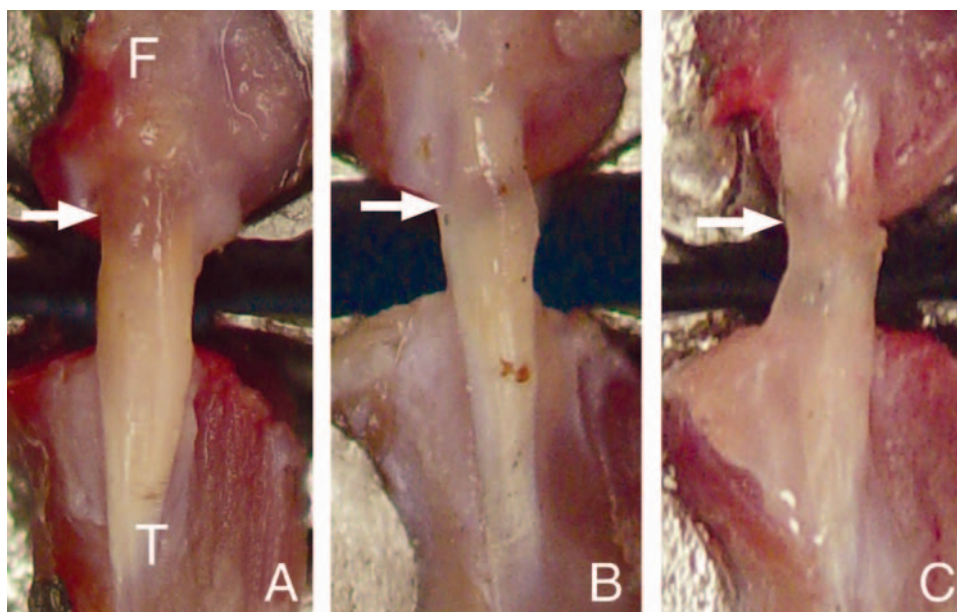


Figure 4. Representative images of ligaments at (A) 2 weeks, (B) 4 weeks, and (C) 12 weeks after injury. Arrows indicate the location of initial injury. F, femoral origin of the medial collateral ligament. T, tibial insertion of the medial collateral ligament.

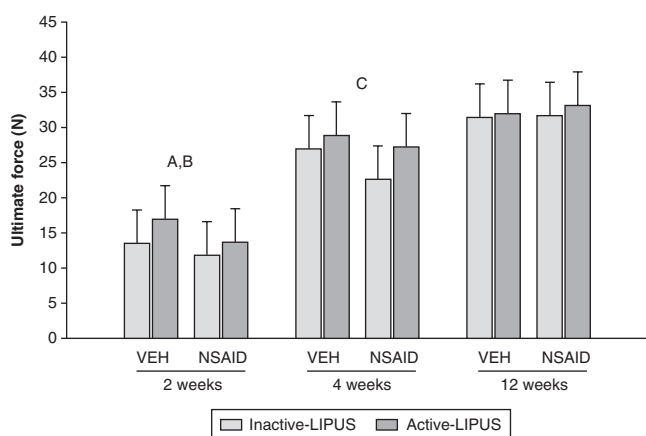


Figure 5. Effect of ultrasound and drug intervention on ligament ultimate force after 2, 4, and 12 weeks of intervention. There were no significant ultrasound \times drug interactions at any time point (all P s $>$.05), as determined by 2-way, 1 repeated-measure analyses of variance. Bars represent mean \pm SD. LIPUS, low-intensity pulsed ultrasound; VEH, vehicle-treated group; NSAID, nonsteroidal anti-inflammatory-treated group; A, significant ultrasound main effect ($P <$.02); B, significance approached for drug main effect ($P =$.07); C, significance approached for ultrasound main effect ($P =$.09).

2 weeks (scar failure, 56/56 ligaments) than in the groups treated for 12 weeks (scar failure, 20/32 ligaments) ($P <$.05).

There were no significant interactions between ultrasound and drug intervention on ligament ultimate force, stiffness, or energy to failure at any time point (all P s = .23-.97). At 2 weeks, however, the mean percentage difference in ultimate force between ligaments treated with active and inactive LIPUS was 34.2% (95% CI, 6.0%-62.3%; $P <$.02), indicating

that ultrasound-treated ligaments were stronger (Figure 5). Similarly, at 2 weeks, active LIPUS-treated ligaments were 27.0% (95% CI, 8.4%-45.5%) stiffer ($P <$.01) (Figure 6) and could absorb 54.4% (95% CI, 6.0%-62.3%) more energy before failure ($P =$.03) (Figure 7) than could inactive LIPUS-treated ligaments.

Intervention with an NSAID did not have any effect on ligament stiffness at 2 weeks (mean difference, 0.2 N/mm; 95% CI, -1.9 to 2.2 N/mm) ($P =$.88) (Figure 6); however, ligaments from the NSAID group absorbed 33.3% less energy than did ligaments from the VEH group (mean difference, -2.2 mJ; 95% CI, -4.5 to -0.1 mJ) ($P <$.05) (Figure 7). There was no significant effect of NSAID on ultimate force at 2 weeks; however, significance was approached ($P =$.07) with ligaments from the NSAID group being 19.8% weaker (mean difference, -2.5 N; 95% CI, -5.3 to 0.3 N) than ligaments from the VEH group (Figure 5).

Neither LIPUS nor NSAID had any significant effects on ligament mechanical properties at 4 weeks (all P s = .06-.69) or 12 weeks (all P s = .11-.96) (Figures 5, 6, and 7). At 4 weeks, however, significance was approached for an ultrasound effect on ultimate force ($P =$.09) (Figure 5) and energy to failure ($P =$.06) (Figure 7), with active LIPUS-treated ligaments being 20.9% (95% CI, -3.3% to 45.0%) stronger and able to absorb 41.6% (95% CI, -0.1% to 83.4%) more energy than inactive LIPUS-treated ligaments. Similarly, at 4 weeks, significance was approached for a drug effect on stiffness, with ligaments from NSAID-treated animals being 12.9% less stiff than ligaments from VEH animals (mean difference, -2.6 N/mm; 95% CI, -5.7 to 0.5 N/mm) ($P =$.09) (Figure 6).

DISCUSSION

This study investigated the individual and combined effects of LIPUS and an NSAID (celecoxib, a selective COX-2

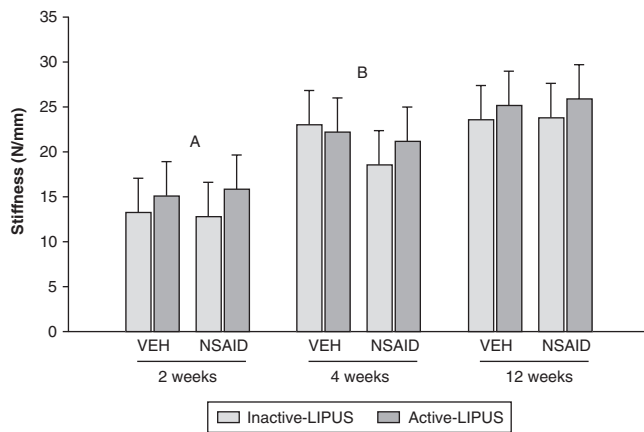


Figure 6. Effect of ultrasound and drug intervention on ligament stiffness after 2, 4, and 12 weeks of intervention. There were no significant ultrasound \times drug interactions at any time point (all P s $>$.05), as determined by 2-way, 1 repeated-measure analyses of variance. Bars represent mean \pm SD. LIPUS, low-intensity pulsed ultrasound; VEH, vehicle-treated group; NSAID, nonsteroidal anti-inflammatory-treated group; A, significant ultrasound main effect ($P <$.01); B, significance approached for drug main effect ($P =$.09).

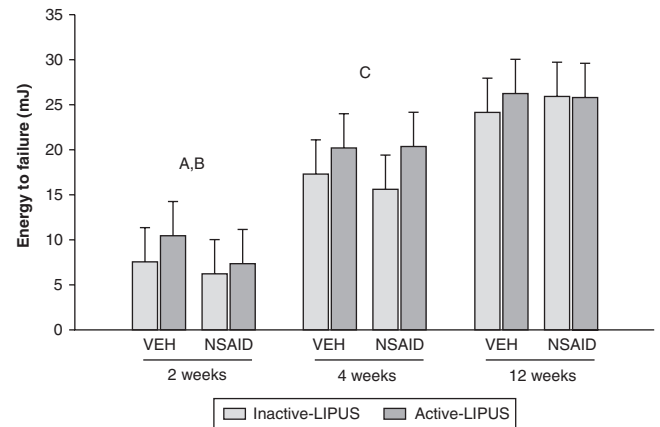


Figure 7. Effect of ultrasound and drug intervention on ligament energy to failure after 2, 4, and 12 weeks of intervention. There were no significant ultrasound \times drug interactions at any time point (all P s $>$.05), as determined by 2-way, 1 repeated-measure analyses of variance. Bars represent mean \pm SD. LIPUS, low-intensity pulsed ultrasound; VEH, vehicle-treated group; NSAID, nonsteroidal anti-inflammatory-treated group; A, significant ultrasound main effect ($P =$.03); B, significant drug main effect ($P <$.05); C, significance approached for ultrasound main effect ($P =$.06).

inhibitor) on acute ligament healing in an animal model. Based on tests of ligament mechanical properties, LIPUS had a beneficial effect on healing, whereas the NSAID had a negative effect. Because these effects were evident only during the early stages of healing and did not persist longer term, they indicate that LIPUS accelerated but did not improve healing and that the NSAID delayed but did not impair healing. This study also found that LIPUS and the NSAID did not work synergistically to influence ligament healing, suggesting that the beneficial LIPUS effect was not dependent on an active COX-2 pathway.

The beneficial LIPUS effect in the current study was not unexpected. LIPUS refers to pulsed-wave ultrasound with an I_{SATA} equal to or lower than 100 mW/cm^2 . This intensity is categorized as low relative to the range that is commonly used in physical therapy ($0.5\text{--}2 \text{ W/cm}^2$).^{27,30} Although the low intensities associated with LIPUS have traditionally been thought to have minimal biological effects and no therapeutic value, recent evidence has demonstrated that significant beneficial effects can be generated when they are applied to injured connective tissues. In particular, clinical trials have shown LIPUS to accelerate the rate of fracture repair in the tibia, radius, and scaphoid by 30% to 38%^{10,11,14} and to stimulate union in 86% of fractures displaying nonunion.¹³ Pooling the tibial, radial, and scaphoid data, a weighted average effect size can be calculated at 6.41.² This figure converts into a mean improvement in healing time of 64 days with LIPUS.

Although established in the intervention of bone injuries,²⁸ recent efforts have been directed toward the effect of LIPUS on injuries to other connective tissues. In terms of ligaments, LIPUS has previously been shown to stimulate

early improvements in the return of mechanical properties after injury.²⁴ The current study confirms this finding and demonstrates that LIPUS accelerates yet does not improve ligament healing. This result was evident by active LIPUS-treated ligaments having superior mechanical properties compared with inactive LIPUS-treated ligaments at early healing time points but not when they were assessed after 12 weeks of intervention. By 12 weeks after injury, both ligaments treated with active and inactive LIPUS had reached the approximate strength of intact MCLs.¹⁹ The early enhancement of ligament mechanical properties with LIPUS is considered to be clinically relevant. At 2 weeks, active LIPUS-treated ligaments were 34% stronger than were inactive LIPUS-treated ligaments. This improvement may conceivably allow earlier return to sport and/or prevent reinjury during initial healing.

The underlying mechanism behind the beneficial LIPUS effect in the current study was not investigated. It is not currently known how ultrasound signals are transduced in vivo to produce a cellular response. However, evidence from in vitro studies suggests that ultrasound may mechanically stimulate reparative fibroblasts, inducing their proliferation and production of collagen.^{5,31,34} Although it is difficult to translate in vitro studies to in vivo situations,²⁹ recent evidence supports the cellular studies by demonstrating that low-intensity ultrasound may enhance ligament healing through events that alter the structural properties of the ligament.²³ Sparrow et al²³ showed healing rabbit MCLs treated with low-intensity ultrasound to have a larger cross-sectional area and a greater proportion of type I collagen fibers than inactive ultrasound-treated ligaments. Because fibroblasts are the producers of collagen during ligament healing, these

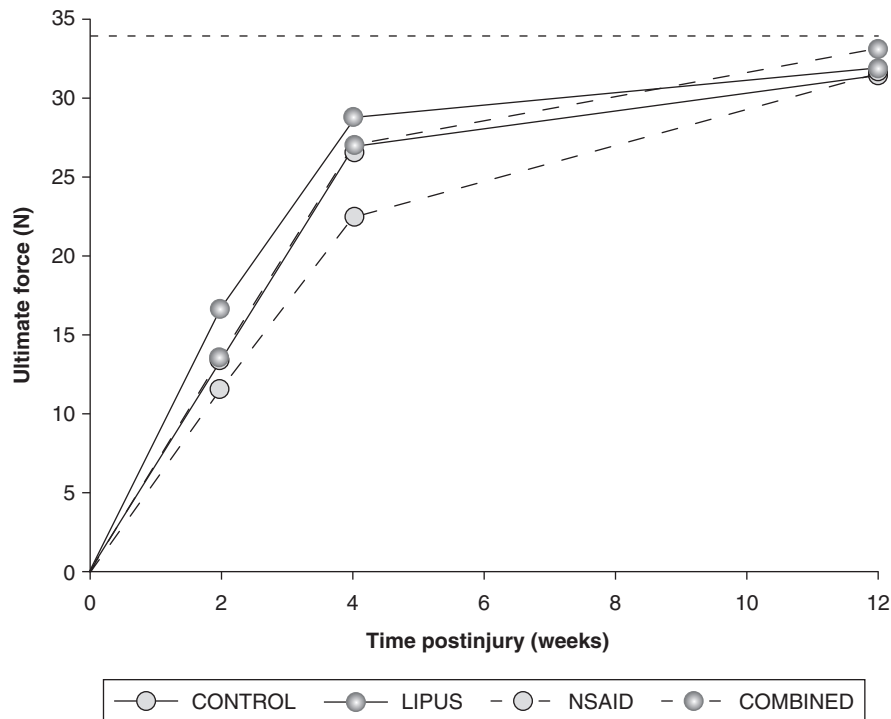


Figure 8. Effect of drug and ultrasound intervention on the time course of ligament healing as determined from ultimate force measures during mechanical testing. The upper (LIPUS; vehicle treated + active LIPUS) and lower (NSAID; NSAID + inactive LIPUS) lines indicate the individual beneficial and detrimental effects of low-intensity pulsed ultrasound (LIPUS) and nonsteroidal anti-inflammatory drugs (NSAIDs), respectively. The middle 2 lines indicate that combined intervention (COMBINED; NSAID + active LIPUS) is equivalent to normal ligament healing (CONTROL; vehicle treated + inactive LIPUS). The dashed horizontal line represents the strength of body weight-matched intact rat medial collateral ligaments, as determined by Provenzano et al.¹⁹

findings indicate that LIPUS may have a beneficial effect on ligament healing via a direct effect on fibroblasts.

In comparison to LIPUS, an NSAID was found to have a negative effect on ligament healing in the current study. Nonsteroidal anti-inflammatory drugs are used after acute injury to reduce inflammation and facilitate the commencement of active rehabilitation by alleviating pain. While clinically effective in this role after ligament injury,^{3,6} questions have been raised regarding the long-term tissue-level effects of NSAIDs when taken during healing.²⁶ By inhibiting COX-2 enzyme activity, NSAIDs exert their predominant effects on acute inflammation. Induced COX-2 expression is the rate-limiting step in the formation of prostaglandins from arachidonic acid after injury. Because prostaglandins cause blood vessel dilation and increase local vascular permeability to potentiate inflammation,⁴ inhibition of COX-2 is considered useful after acute injury. However, COX-2 expression and prostaglandin synthesis are also important in the synthesis of connective tissues. For example, inhibition of COX-2 in the skeleton eliminates or reduces the osteogenic response to mechanical loading^{8,12} and reduces healing in response to experimental fracture.^{22,33} In terms of ligaments, inhibition of COX-2 has been shown to have a negative effect on ligament healing. Elder et al⁷ showed inhibition of COX-2 using celecoxib to negatively influence MCL healing when assessed 12 days after injury. The current study supports

this finding and demonstrates that NSAID use after acute ligament injury delays but does not impair ligament healing. This result was evident by ligaments in NSAID-treated animals having inferior mechanical properties at early healing time points, yet not when they were assessed after 12 weeks of intervention. By 12 weeks after initial injury, ligaments from both NSAID- and VEH-treated animals had reached the approximate strength of intact MCLs.¹⁹

In addition to studying the individual effects of LIPUS and an NSAID on ligament healing, the current study also investigated their combined effects. This step is important because interventions are frequently used in combination in clinical practice. Also, previous evidence suggested that LIPUS has its beneficial effects during tissue healing via the stimulation of COX-2.^{15,21,29} However, the current study found no interactive effects between LIPUS and an NSAID, suggesting that the NSAID did not influence the effect of LIPUS during ligament healing. The LIPUS and the NSAID did not work in synergy, so their effects on knee ligament healing are additive. Therefore, we need to summate their individual effects to establish their combined effect. Because LIPUS and the NSAID had opposing effects that were approximately equal in magnitude, their combined effect is equivalent to the introduction of no intervention at all. This finding is most clearly demonstrated by plotting the ultimate force data from the current study against time (Figure 8). Ligaments

exposed to both the NSAID and active LIPUS (combined group representation) (Figure 1) had the same ultimate force during early healing as ligaments exposed to VEH and inactive LIPUS (control group representation) (Figure 1).

The results of the current study suggest that LIPUS may be used clinically after acute ligament injury to facilitate earlier return to activity, whereas NSAIDs should be avoided, as they may elevate early reinjury risk. In addition, the data suggest that combined LIPUS and NSAID intervention should not be used during early ligament healing, as the NSAID negated the beneficial LIPUS effect. However, it is not possible to make such clinical paradigms based on the translation of animal data. Assessment of the mechanical properties of the ligaments was the chosen outcome measure in the current study because the restoration of mechanical integrity is the overall function of any repair process in a load-bearing structure. However, clinically, other factors contribute to the attainment of a functional outcome; these include pain and swelling, which are both influenced by NSAIDs during the early stages of healing. It is possible that the clinically beneficial effects of NSAIDs on pain and swelling outweigh the drugs' possible detrimental effect on tissue-level repair. Based on this study, however, it is recommended that NSAID use after acute injury be only for as long as necessary to alleviate symptoms. It is likely, based on studies into NSAID effects on experimental fractures,¹⁶ that short-term NSAID use (a few days) does not influence tissue-level healing. This idea requires further investigation in ligament injuries. Also, the current data need to be carefully interpreted given the nonphysiological mechanism of injury (surgical transection), which contrasts the typical strain injuries observed clinically.

In summary, this study found LIPUS accelerated but did not improve ligament healing, whereas an NSAID delayed but did not impair healing. When used in combination, the beneficial LIPUS effect was cancelled by the detrimental NSAID effect. Although these findings support a theoretically sound argument for the use of LIPUS and nonuse of an NSAID after acute ligament injury, careful interpretation of this controlled laboratory study is warranted until its findings are confirmed by clinical studies.

ACKNOWLEDGMENT

This work was funded by a grant-in-aid from the Indiana University–Purdue University Indianapolis Office for Professional Development. Portions of the work were presented at the 2005 Australian Conference of Science and Medicine in Sport (Melbourne, Victoria, Australia), where it was awarded the ASICS Award for Best Young Investigator by the Australian Sports Medicine Federation Fellows.

REFERENCES

- Bouter LM. Insufficient scientific evidence for efficacy of widely used electrotherapy, laser therapy, and ultrasound treatment in physiotherapy. *Ned Tijdschr Geneeskd.* 2000;144:502-505.
- Busse JW, Bhandari M, Kulkarni AV, Tunks E. The effect of low-intensity pulsed ultrasound therapy on time to fracture healing: a meta-analysis. *Can Med Assoc J.* 2002;166:437-441.
- Buvanendran A, Kroin JS, Tuman KJ, et al. Effects of perioperative administration of a selective cyclooxygenase 2 inhibitor on pain management and recovery of function after knee replacement: a randomized controlled trial. *JAMA.* 2003;290:2411-2418.
- Cirino G. Multiple controls in inflammation: extracellular and intracellular phospholipase A2, inducible and constitutive cyclooxygenase, and inducible nitric oxide synthase. *Biochem Pharmacol.* 1998;55:105-111.
- Doan N, Reher P, Meghji S, Harris M. In vitro effects of therapeutic ultrasound on cell proliferation, protein synthesis, and cytokine production by human fibroblasts, osteoblasts, and monocytes. *J Oral Maxillofac Surg.* 1999;57:409-419.
- Ekman EF, Fiechtner JJ, Levy S, Fort JG. Efficacy of celecoxib versus ibuprofen in the treatment of acute pain: a multicenter, double-blind, randomized controlled trial in acute ankle sprain. *Am J Orthop.* 2002;31:445-451.
- Elder CL, Dahners LE, Weinhold PS. A cyclooxygenase-2 inhibitor impairs ligament healing in the rat. *Am J Sports Med.* 2001;29:801-805.
- Forwood MR. Inducible cyclo-oxygenase (COX-2) mediates the induction of bone formation by mechanical loading in vivo. *J Bone Miner Res.* 1996;11:1688-1693.
- Gam AN, Johannsen F. Ultrasound therapy in musculoskeletal disorders: a meta-analysis. *Pain.* 1995;63:85-91.
- Heckman JD, Ryaby JP, McCabe J, Frey JJ, Kilcoyne RF. Acceleration of tibial fracture-healing by non-invasive, low-intensity pulsed ultrasound. *J Bone Joint Surg Am.* 1994;76:26-34.
- Kristiansen TK, Ryaby JP, McCabe J, Frey JJ, Roe LR. Accelerated healing of distal radius fractures with the use of specific, low-intensity ultrasound. *J Bone Joint Surg Am.* 1997;79:961-973.
- Li J, Burr DB, Turner CH. Suppression of prostaglandin synthesis with NS-398 has different effects on endocortical and periosteal bone formation induced by mechanical loading. *Calcif Tissue Int.* 2002;70:320-329.
- Mayr E, Frankel V, Rüter A. Ultrasound: an alternative healing method for nonunions? *Arch Orthop Trauma Surg.* 2000;120:1-8.
- Mayr E, Rutzki MM, Rutzki M, Borchardt B, Hausser H, Rüter A. Beschleunigt niedrig intensiver, gepulster Ultraschall die Heilung von Skaphoidfrakturen? *Handchir Mikrochir Plast Chir.* 2000;32:115-122.
- Naruse K, Mikuni-Takagaki Y, Azuma Y, et al. Anabolic response of mouse bone-marrow-derived stromal cell clonal ST2 cells to low-intensity pulsed ultrasound. *Biochem Biophys Res Commun.* 2000;268:216-220.
- O'Connor JP, Simon AM. Sustained inhibition of COX-2 decreases fracture healing success [abstract]. *J Bone Miner Res.* 2003;18:S338.
- Paulson SK, Hribar JD, Liu NW, et al. Metabolism and excretion of [(14)C]celecoxib in healthy male volunteers. *Drug Metab Dispos.* 2000;28:308-314.
- Paulson SK, Zhang JY, Breau AP, et al. Pharmacokinetics, tissue distribution, metabolism, and excretion of celecoxib in rats. *Drug Metab Dispos.* 2000;28:514-521.
- Provenzano PP, Martinez DA, Grindeland RE, et al. Hindlimb unloading alters ligament healing. *J Appl Physiol.* 2003;94:314-324.
- Robertson VJ, Baker KG. A review of therapeutic ultrasound: effectiveness studies. *Phys Ther.* 2001;81:1339-1350.
- Sena K, Leven RM, Mazhar K, Sumner DR, Virdi AS. Early gene response to low-intensity pulsed ultrasound in rat osteoblastic cells. *Ultrasound Med Biol.* 2005;31:703-708.
- Simon AM, Manigrasso MB, O'Connor JP. Cyclo-oxygenase 2 function is essential for bone fracture healing. *J Bone Miner Res.* 2002;17:963-976.
- Sparrow KJ, Finucane SD, Owen JR, Wayne JS. The effects of low-intensity ultrasound on medial collateral ligament healing in the rabbit model. *Am J Sports Med.* 2005;33:1048-1056.
- Takakura Y, Matsui N, Yoshiya S, et al. Low-intensity pulsed ultrasound enhances early healing of medial collateral ligament injuries in rats. *J Ultrasound Med.* 2002;21:283-288.
- van der Windt DA, van der Heijden GJ, van den Berg SG, ter Riet G, de Winter AF, Bouter LM. Ultrasound therapy for musculoskeletal disorders: a systematic review. *Pain.* 1999;81:257-271.
- Warden SJ. Cyclooxygenase-2 inhibitors (COXIBs): beneficial or detrimental for athletes with acute musculoskeletal injuries? *Sports Med.* 2005;35:271-283.

27. Warden SJ. A new direction for ultrasound therapy in sports medicine. *Sports Med.* 2003;33:95-107.
28. Warden SJ, Bennell KL, McMeeken JM, Wark JD. Acceleration of fresh fracture repair using the Sonic Accelerated Fracture Healing System (SAFHS): a review. *Calcif Tissue Int.* 2000;66:157-163.
29. Warden SJ, Favaloro J, Bennell KL, et al. Low-intensity pulsed ultrasound stimulates a bone-forming response in UMR-106 cells. *Biochem Biophys Res Commun.* 2001;286:443-450.
30. Warden SJ, McMeeken JM. Ultrasound usage and dosage in sports physiotherapy. *Ultrasound Med Biol.* 2002;28:1075-1080.
31. Webster DF, Harvey W, Dyson M, Pond JB. The role of ultrasound-induced cavitation in the 'in vitro' stimulation of collagen synthesis in human fibroblasts. *Ultrasonics.* 1980;18:33-37.
32. Woo SL, Orlando CA, Camp JF, Akeson WH. Effects of postmortem storage by freezing on ligament tensile behavior. *J Biomech.* 1986;19:399-404.
33. Zhang X, Schwarz EM, Young DA, Puzas JE, Rosier RN, O'Keefe RJ. Cyclooxygenase-2 regulates mesenchymal cell differentiation into the osteoblast lineage and is critically involved in bone repair. *J Clin Invest.* 2002;109:1405-1415.
34. Zhou S, Schmelz A, Seufferlein T, Li Y, Zhao J, Bachem MG. Molecular mechanisms of low intensity pulsed ultrasound in human skin fibroblasts. *J Biol Chem.* 2004;279:54463-54469.